



# A simplified nasal canthoplasty technique

Ingrid Allgoewer DECVO  
Animal Eye Practise, Berlin, Germany



# indications for nasal canthoplasty

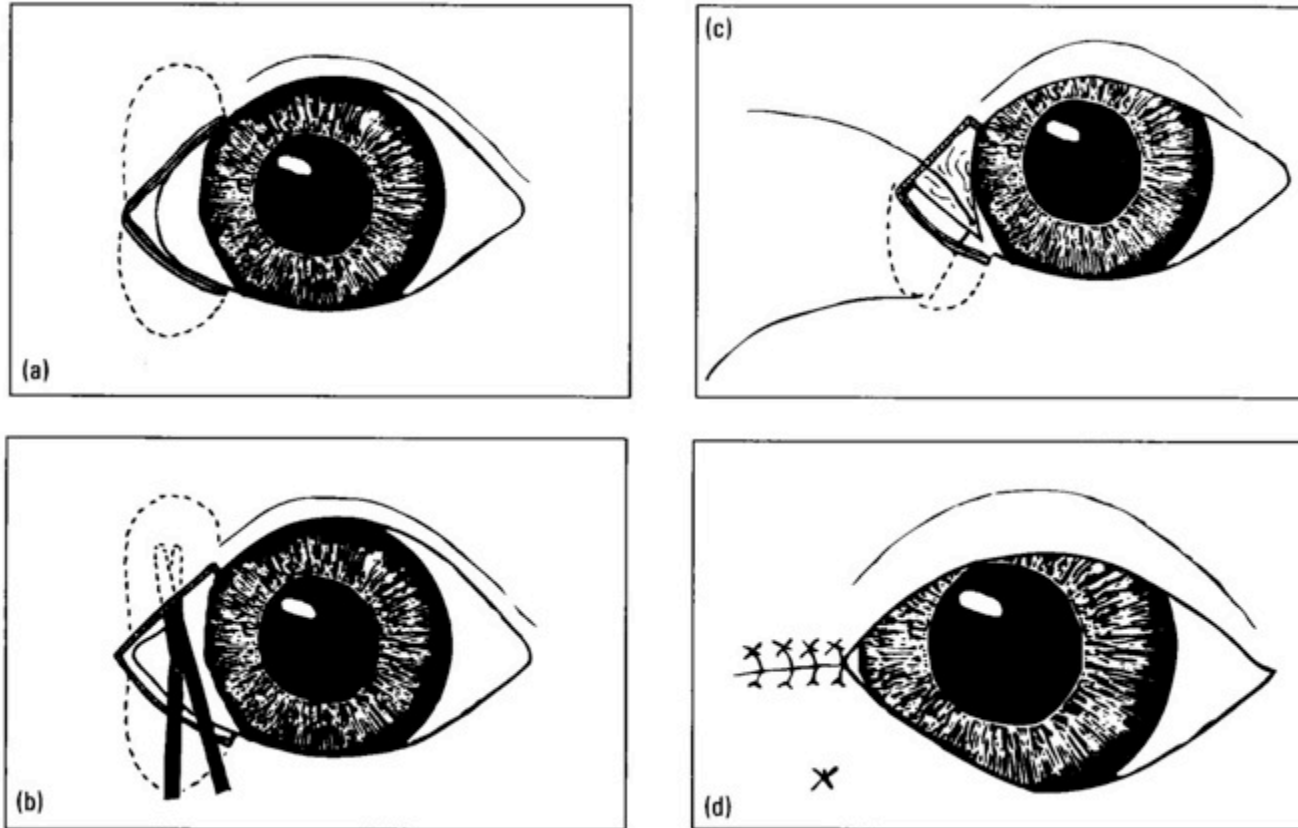
## brachycephalics

- shallow orbit – risk of proptoses/prolaps
- macroblepharon +/- lagophthalmos
- exposure keratitis, KCS
- nasal entropion
- nasal fold trichiasis
- medial trichiasis
- epiphora



# Literature

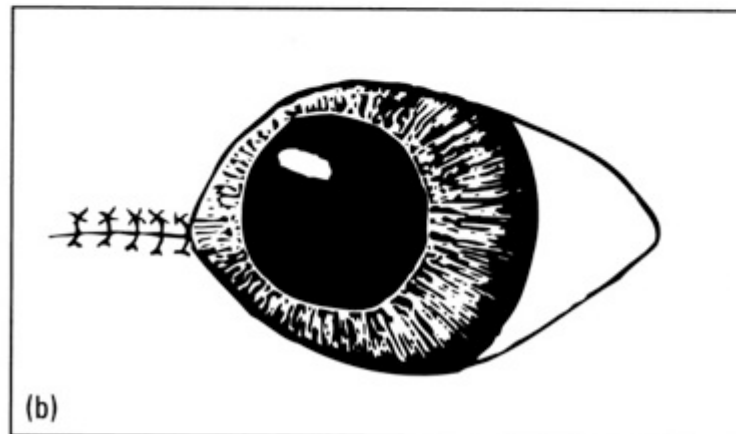
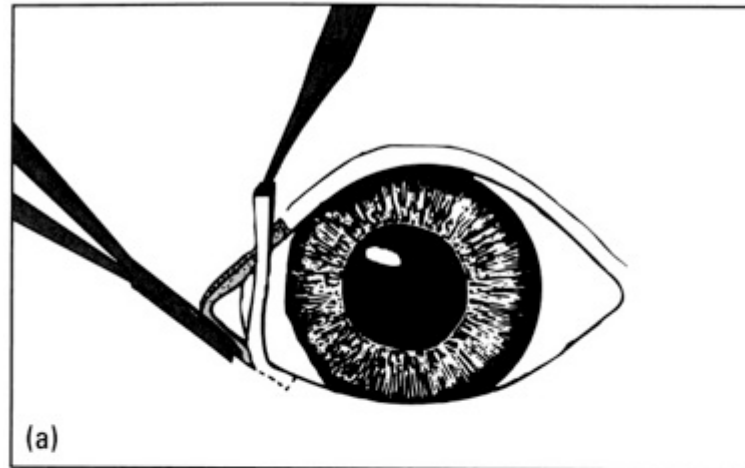
## Roberts-Jensen pocket canthoplasty



Gelatt KN, Gelatt JP. Handbook of Small Animal Ophthalmic Surgery volume 1: Extraocular procedures. New York: Elsevier Science, Inc., 1994.

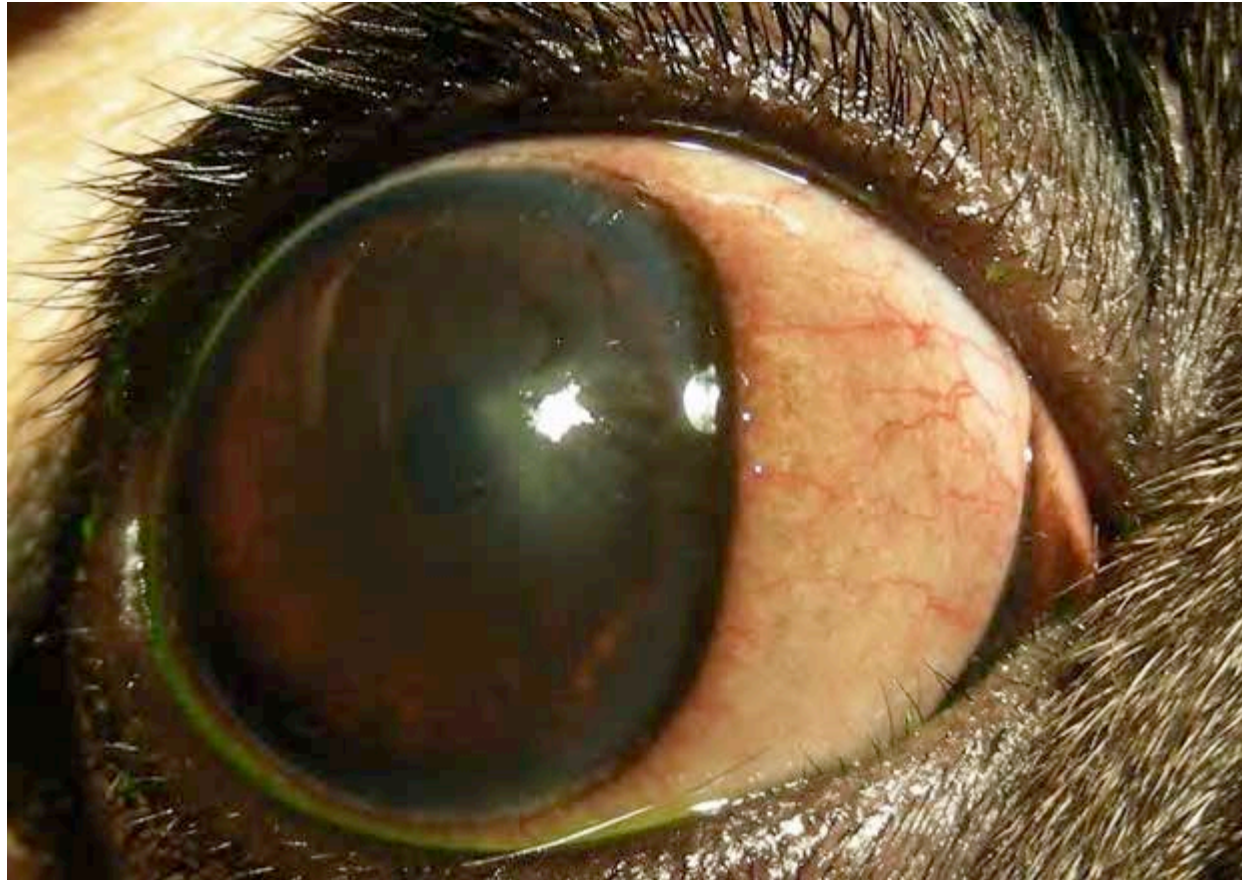# Literature

## Gelatt: medial canthoplasty



Gelatt KN, Gelatt JP. Handbook of Small Animal Ophthalmic Surgery volume 1: Extraocular procedures. New York: Elsevier Science, Inc., 1994.

# nasal canthoplasty



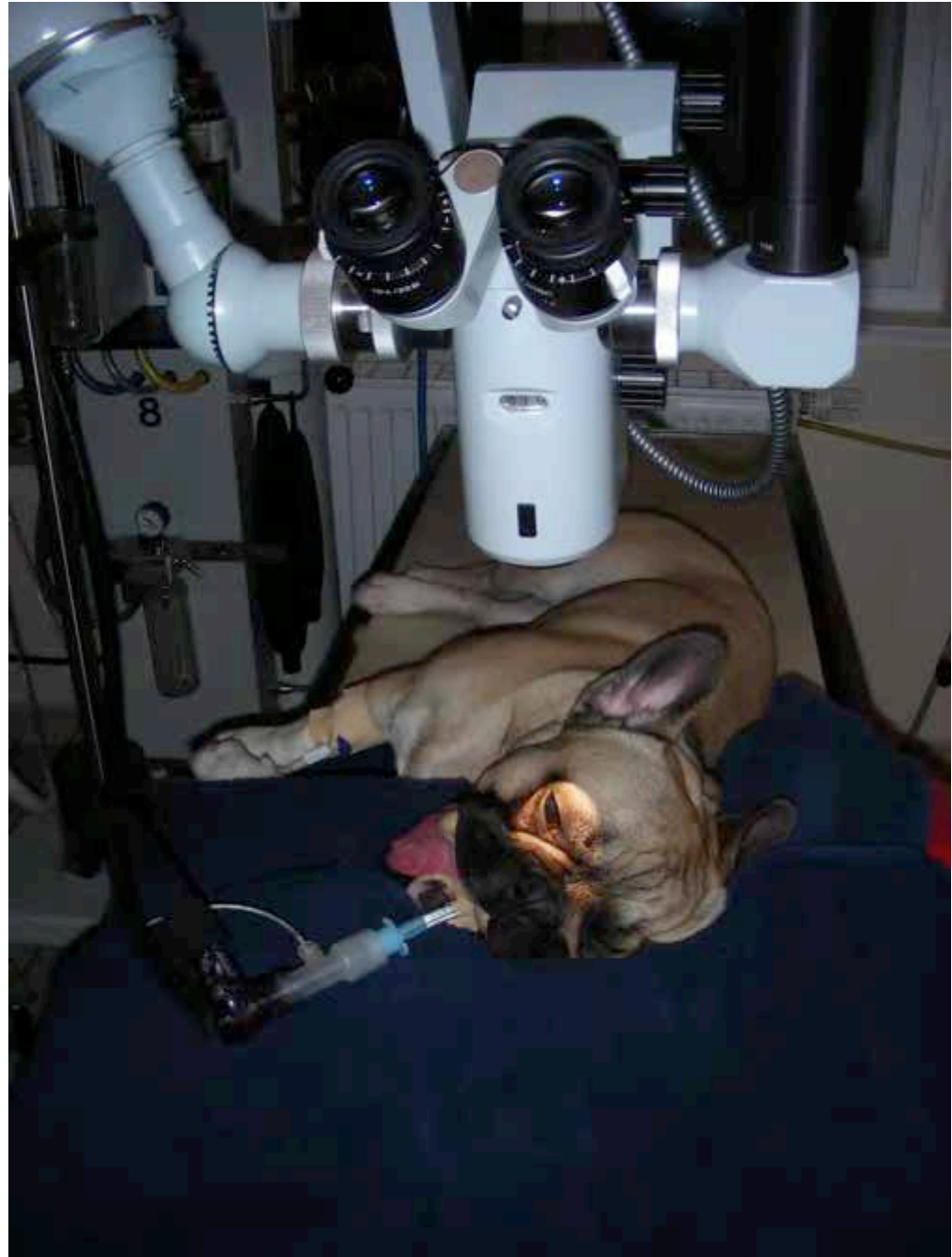- aggressive shortening of the lid fissure may be necessary to be effective
- extend needs to be determined individually

..keep it simple but effective...

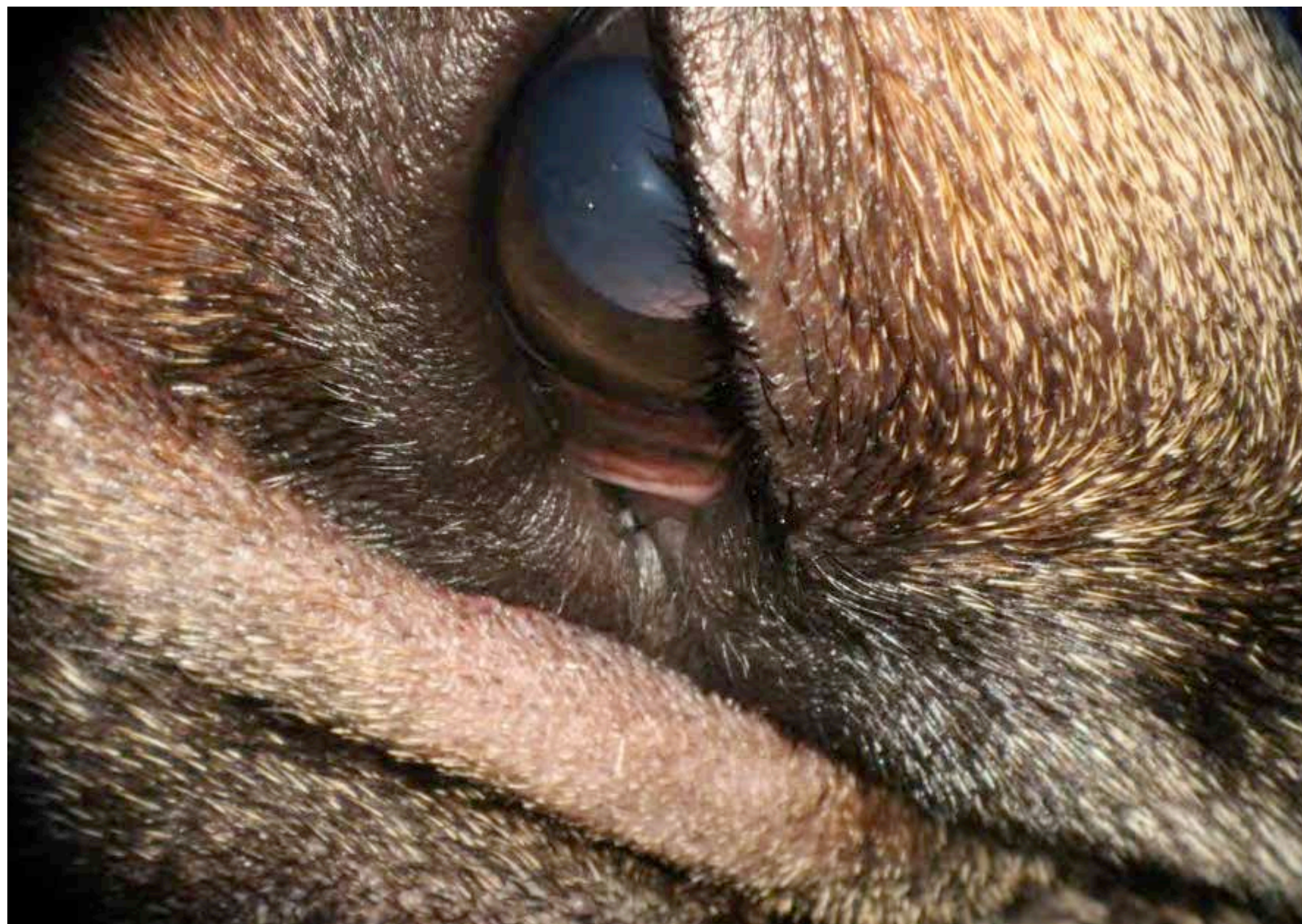
# nasal canthoplasty - preparation

- inhalation anesthesia
- lateral recumbency
- vacuum cushion
- magnification – microscope 5-7x
- instruments
  - fine forceps with tying plates
  - Steven's tenotomy scissors

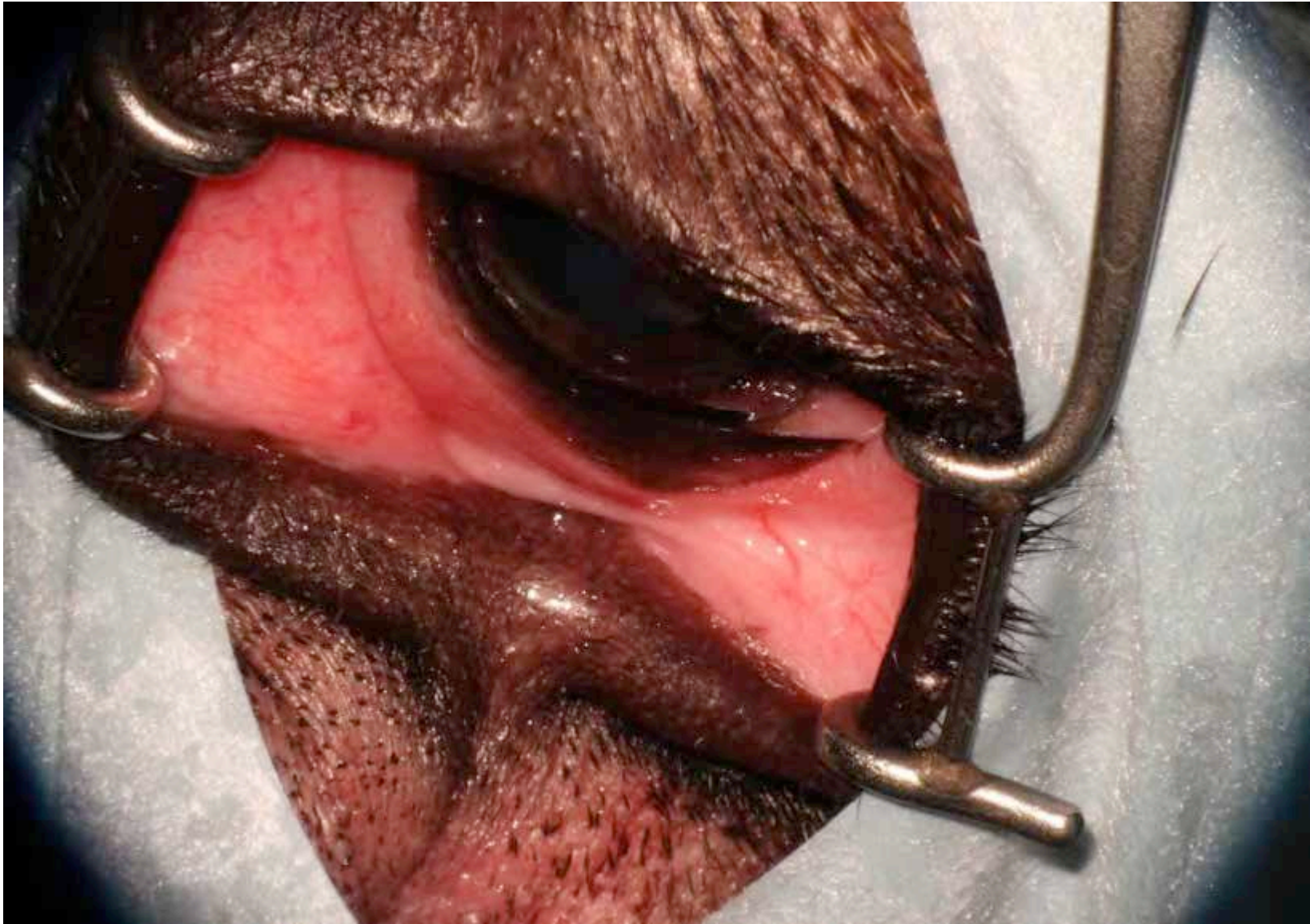positioning







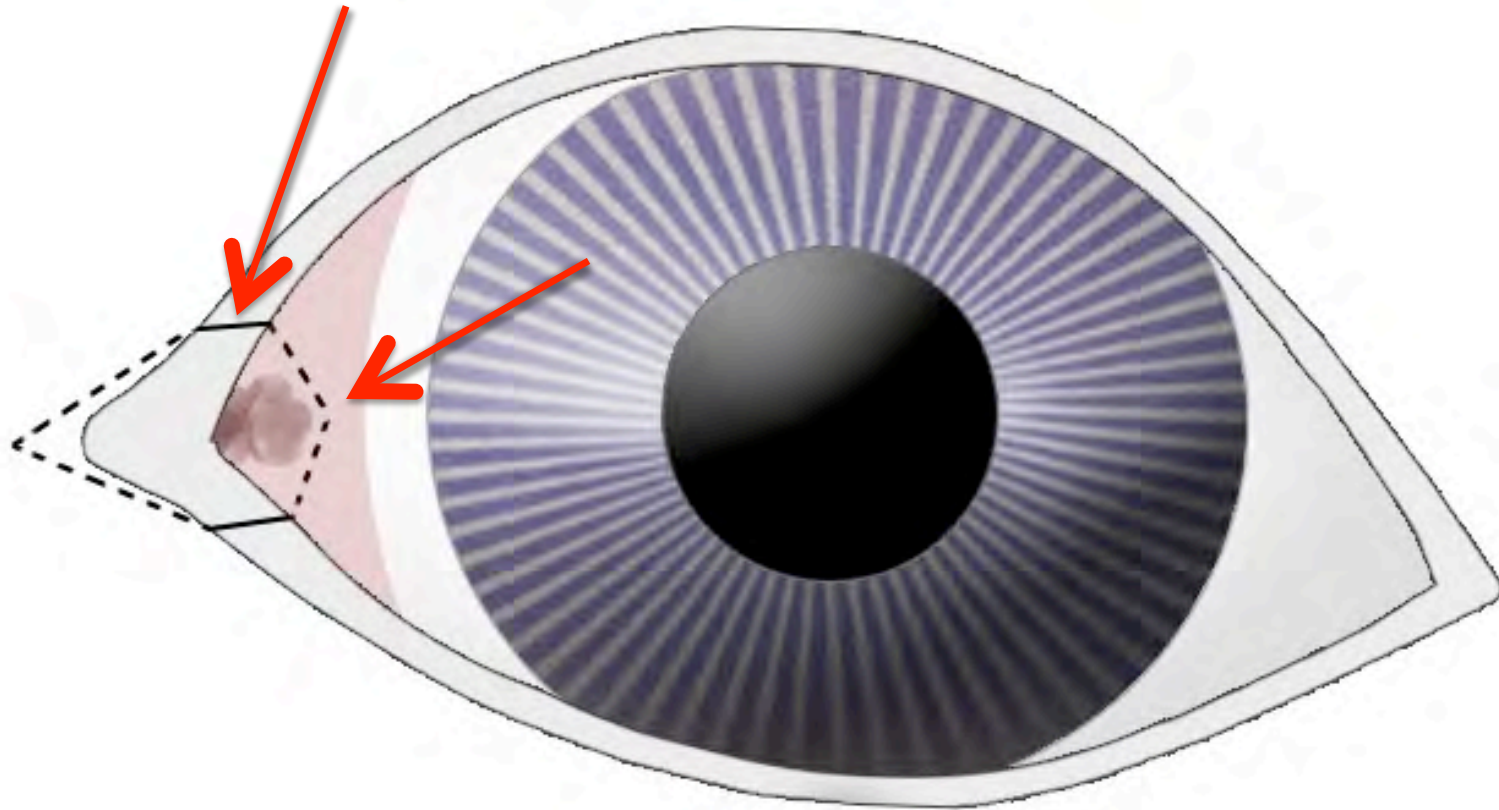


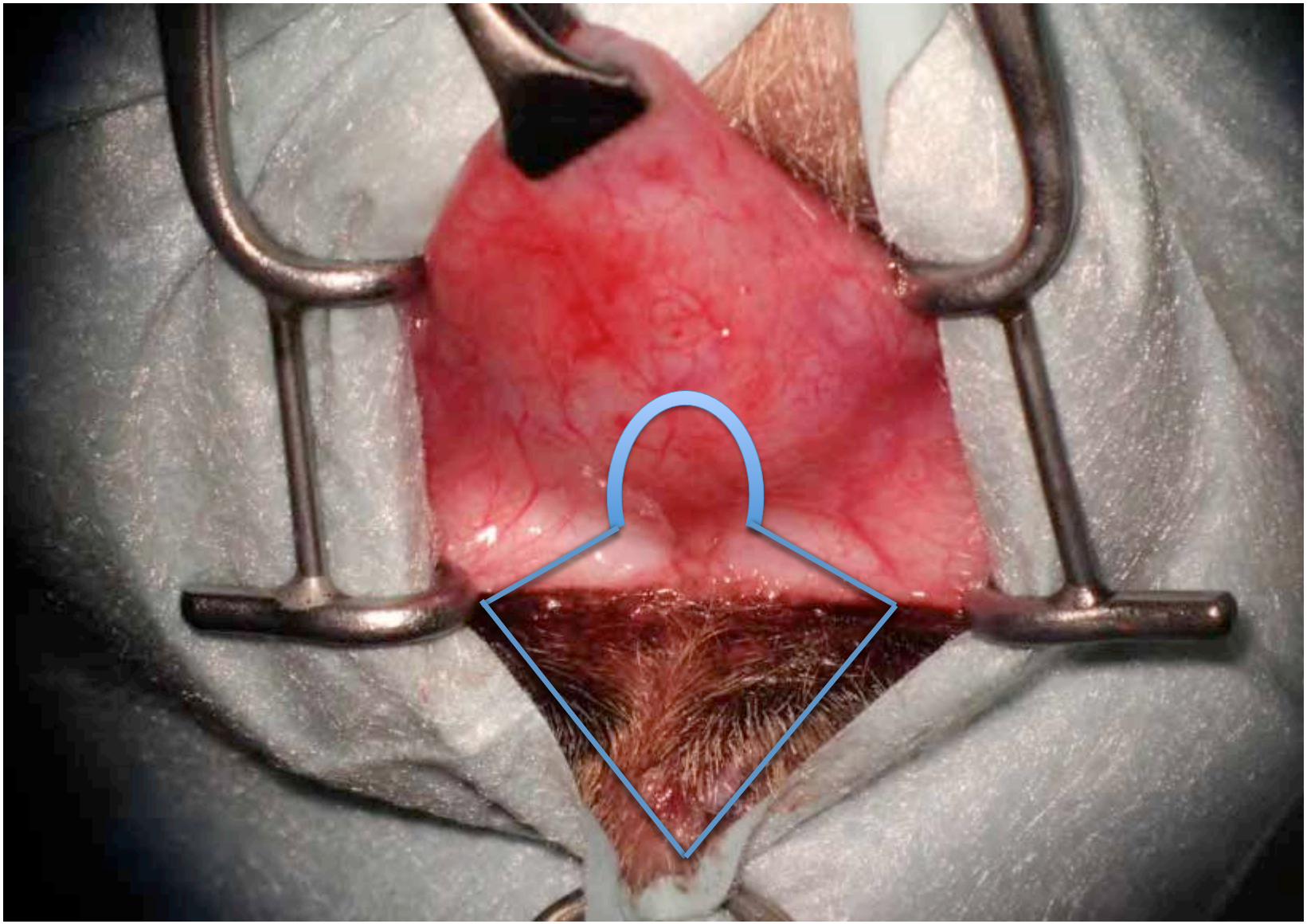


magnification 5-7x necessary

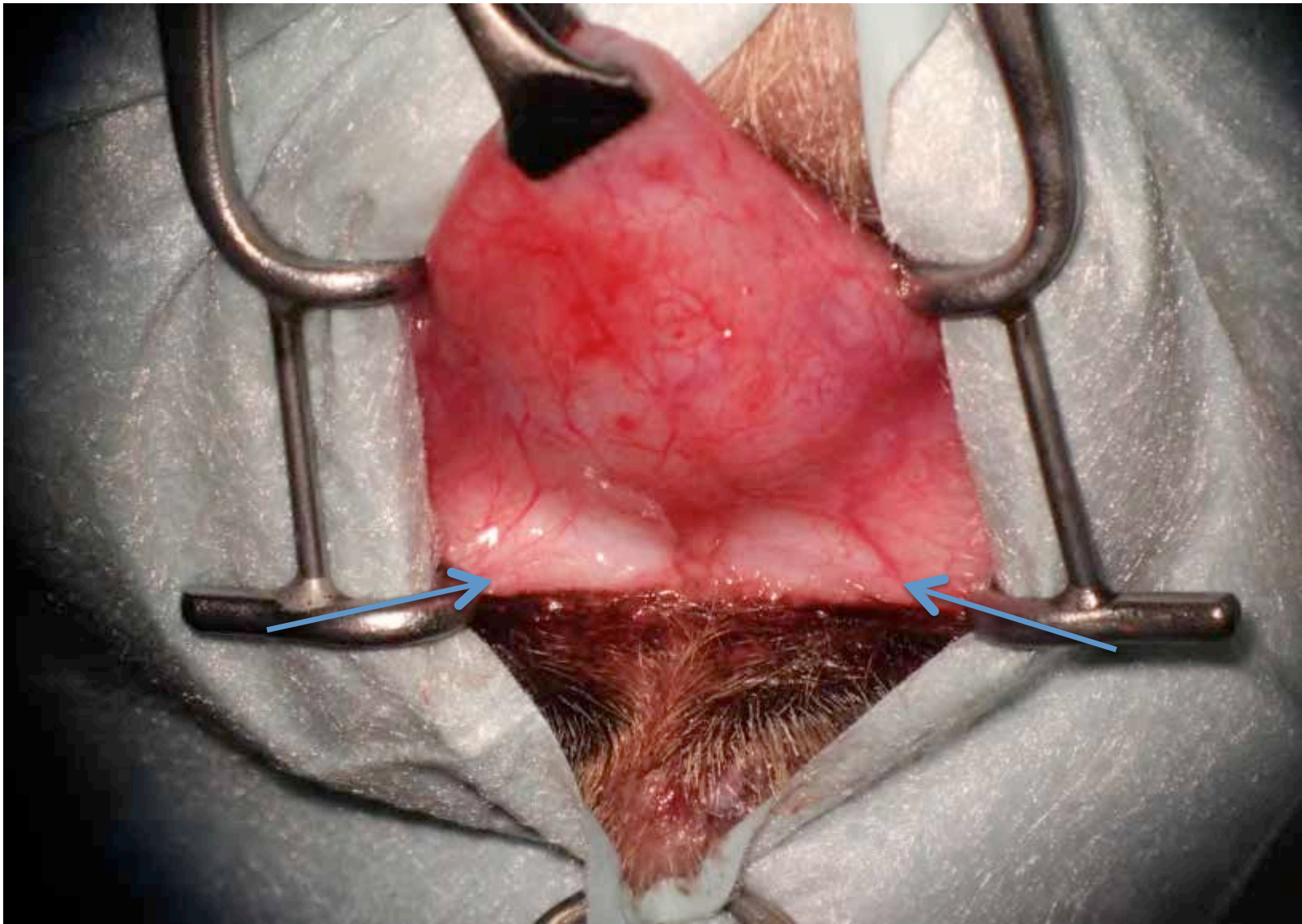


# nasal canthoplasty I

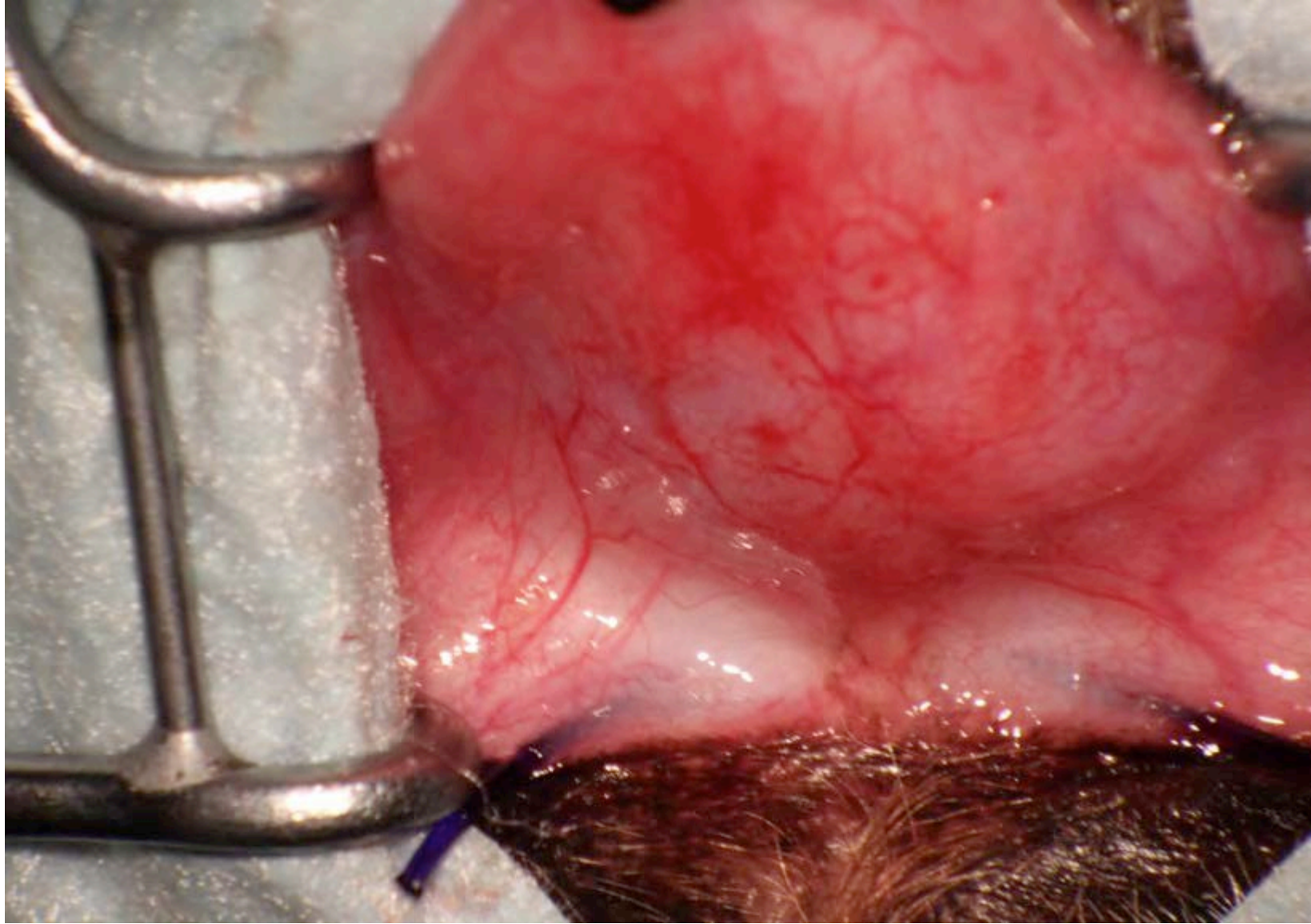




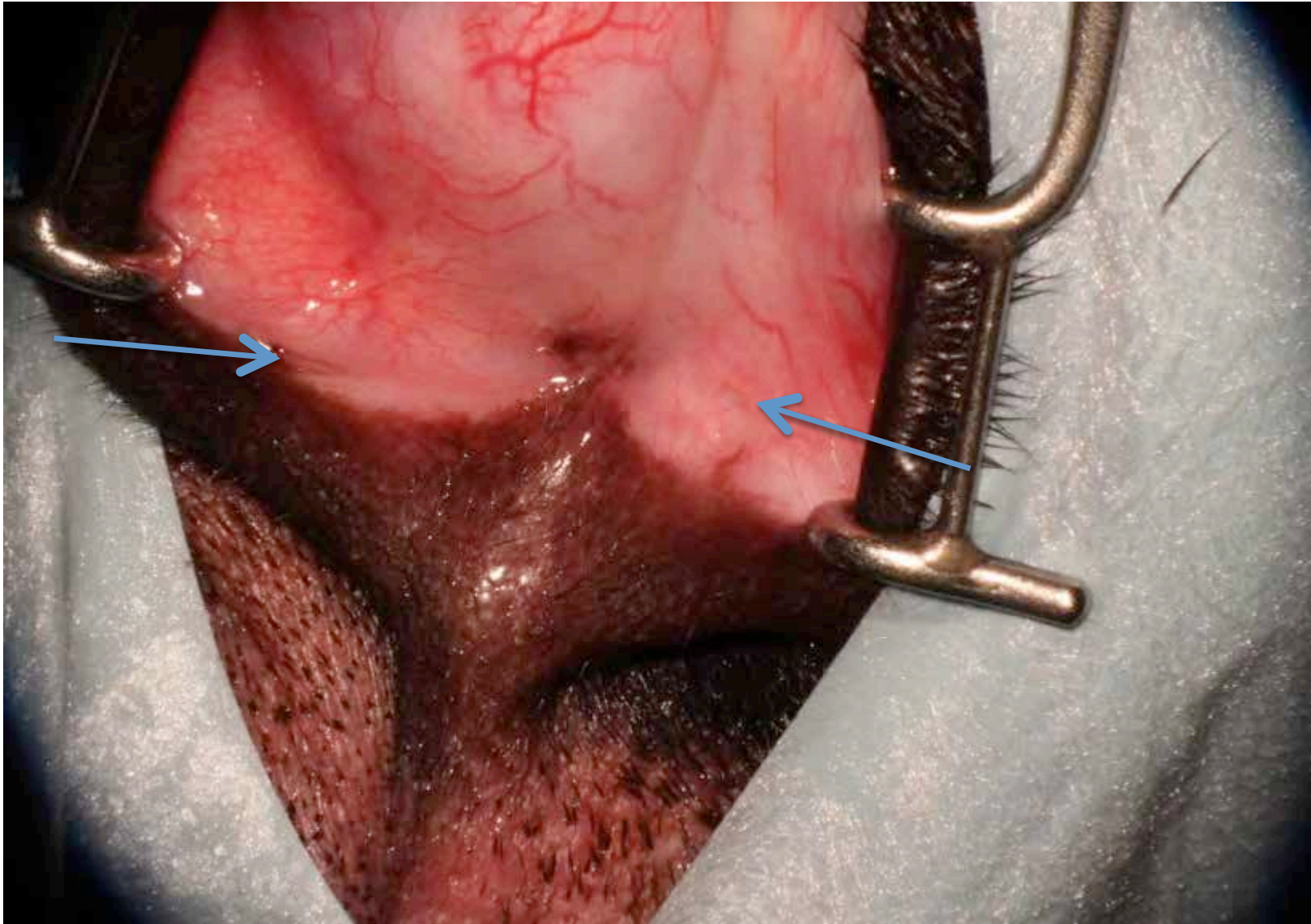


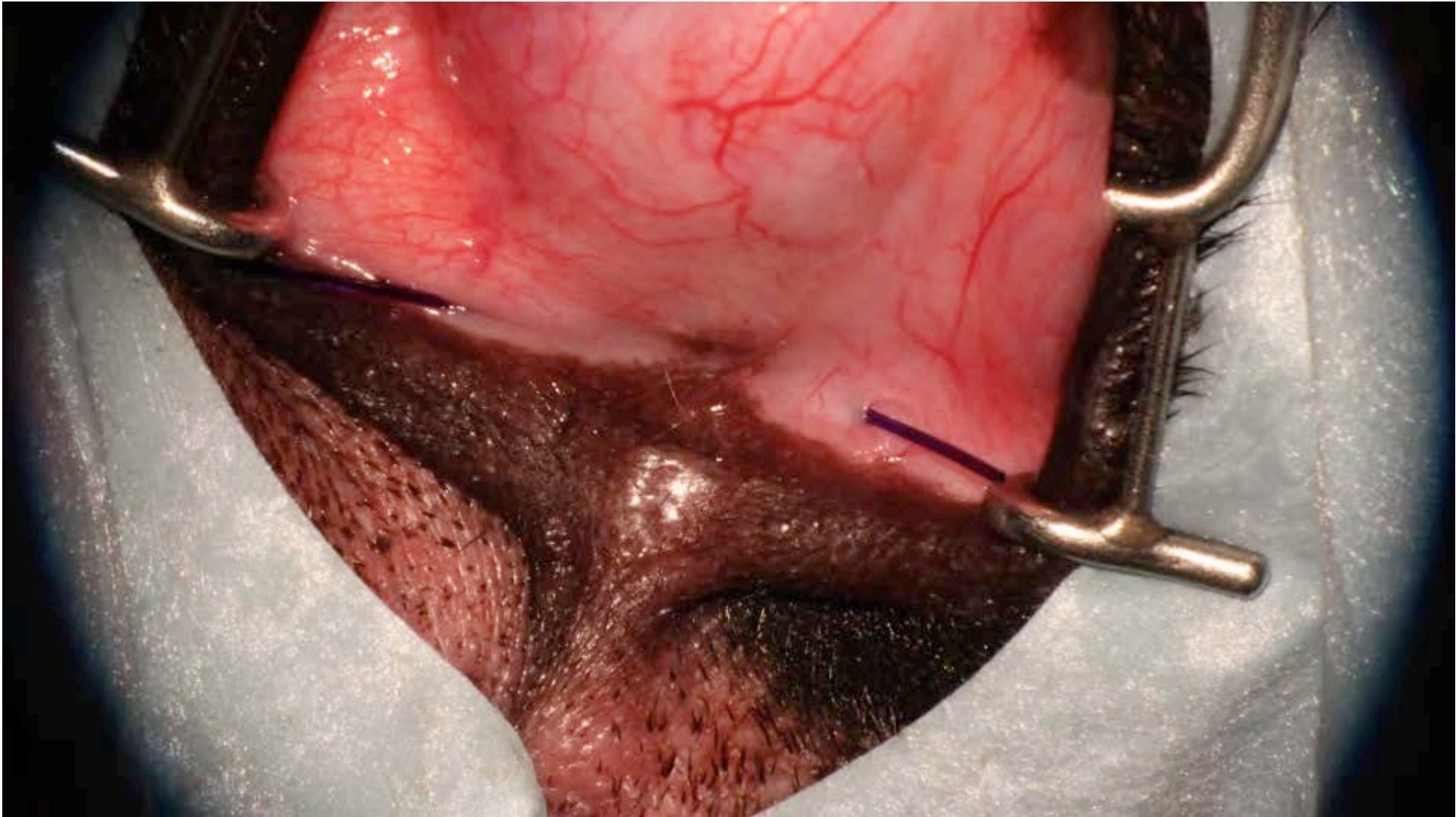


place PDS in canalicula for orientation





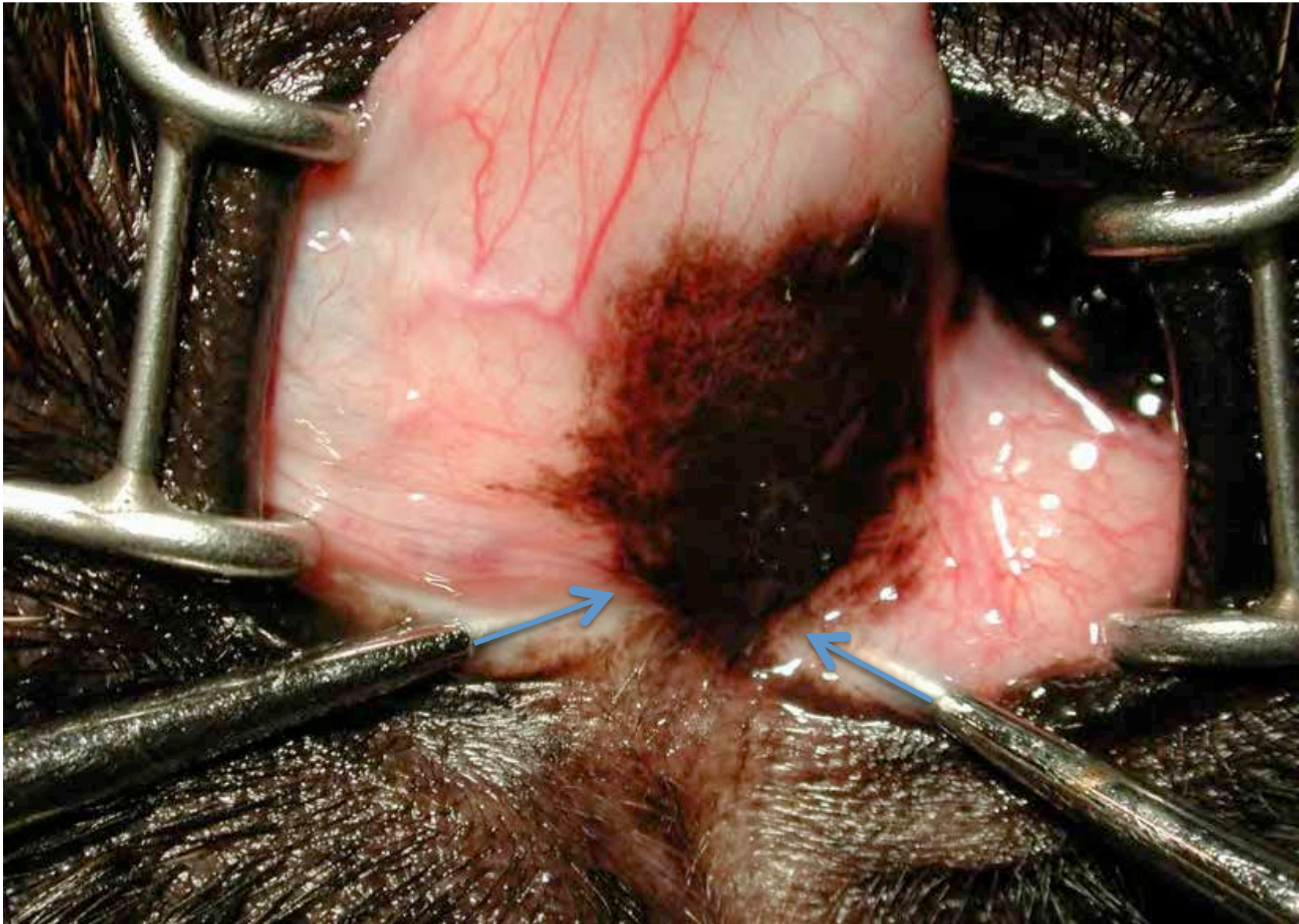




# puncta lacrimalia

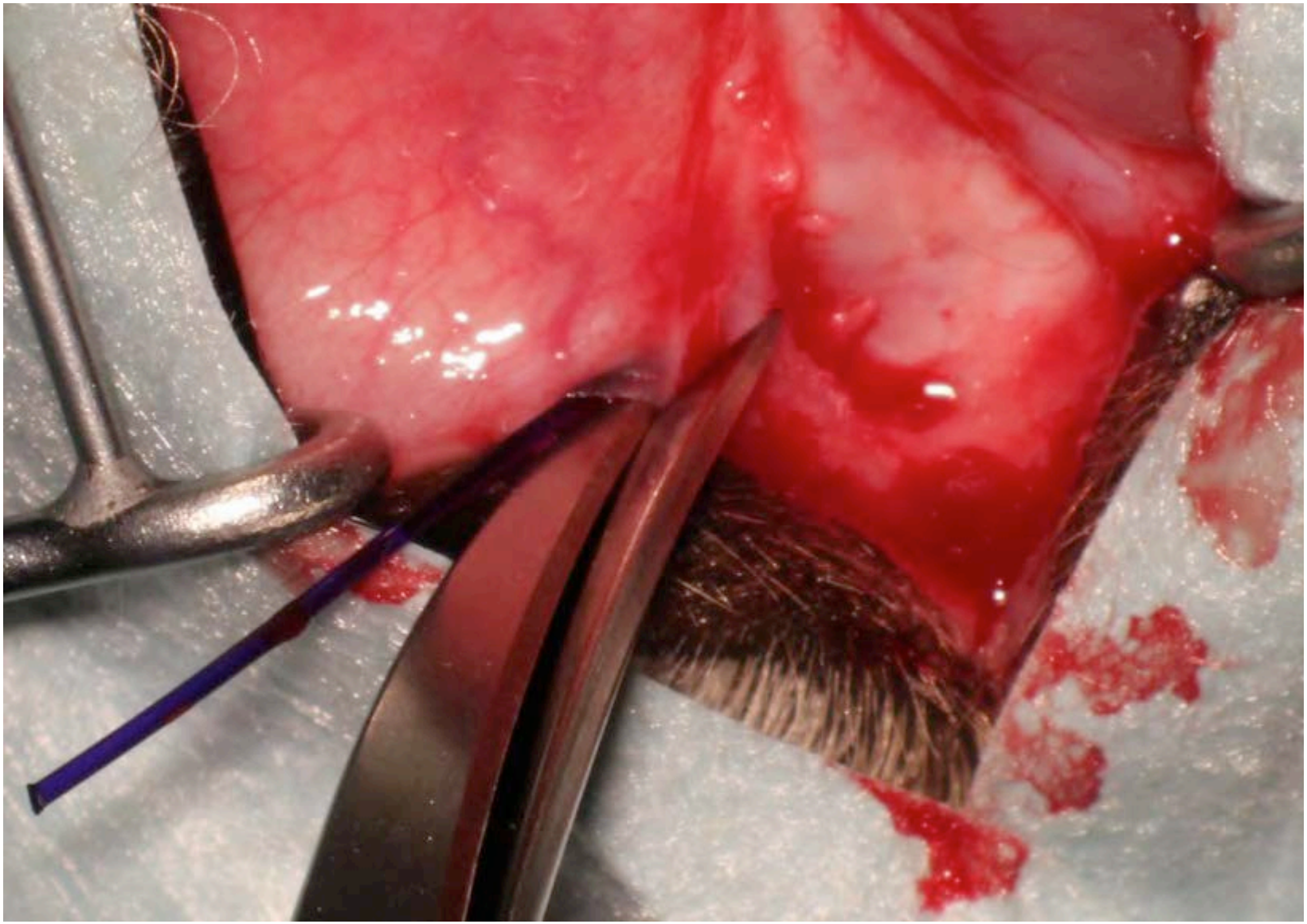
- canaliculi are split
- puncta are “relocated” deeply into the fornix
- indwelling catheter is not necessary
- puncta will remain patent

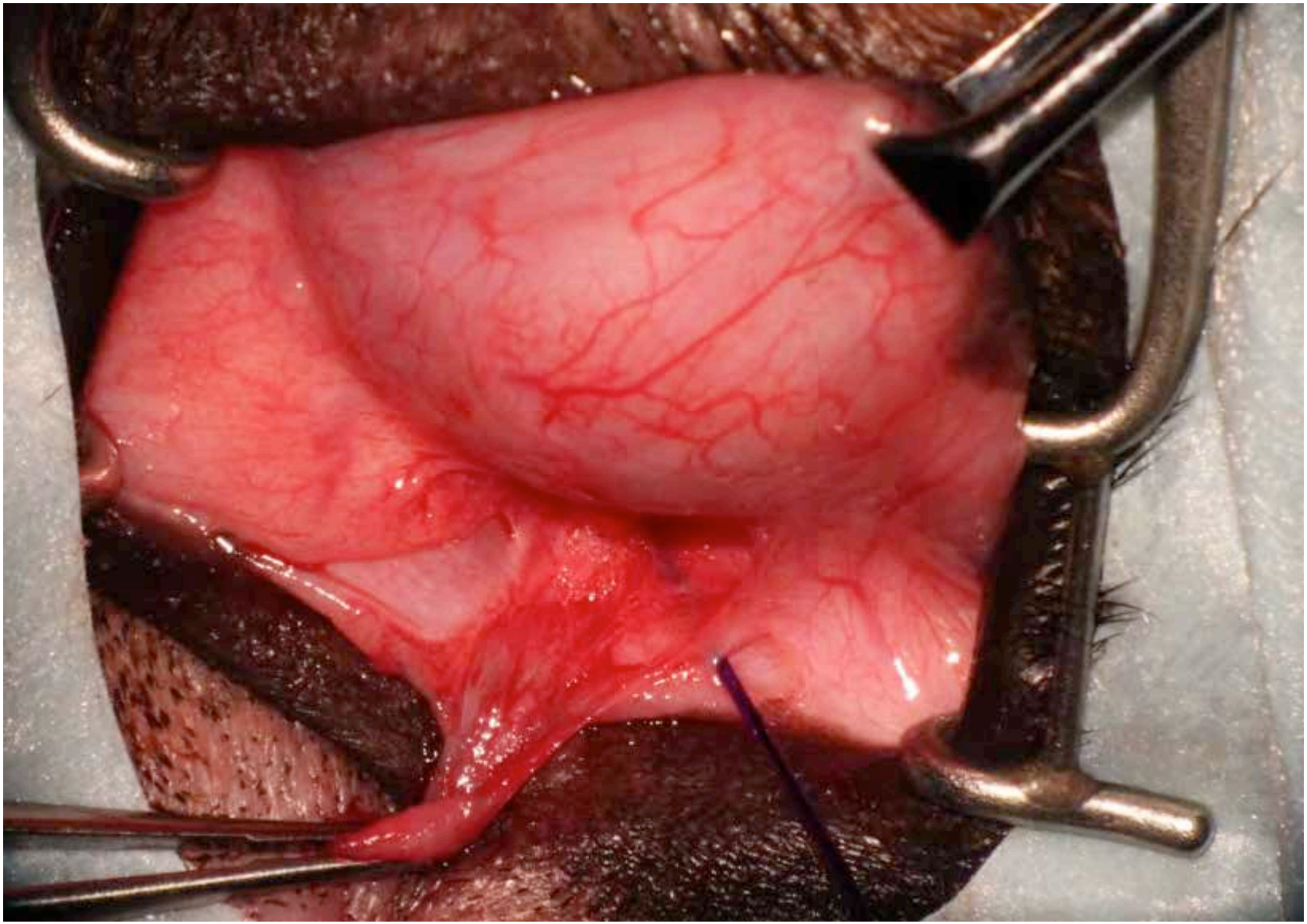




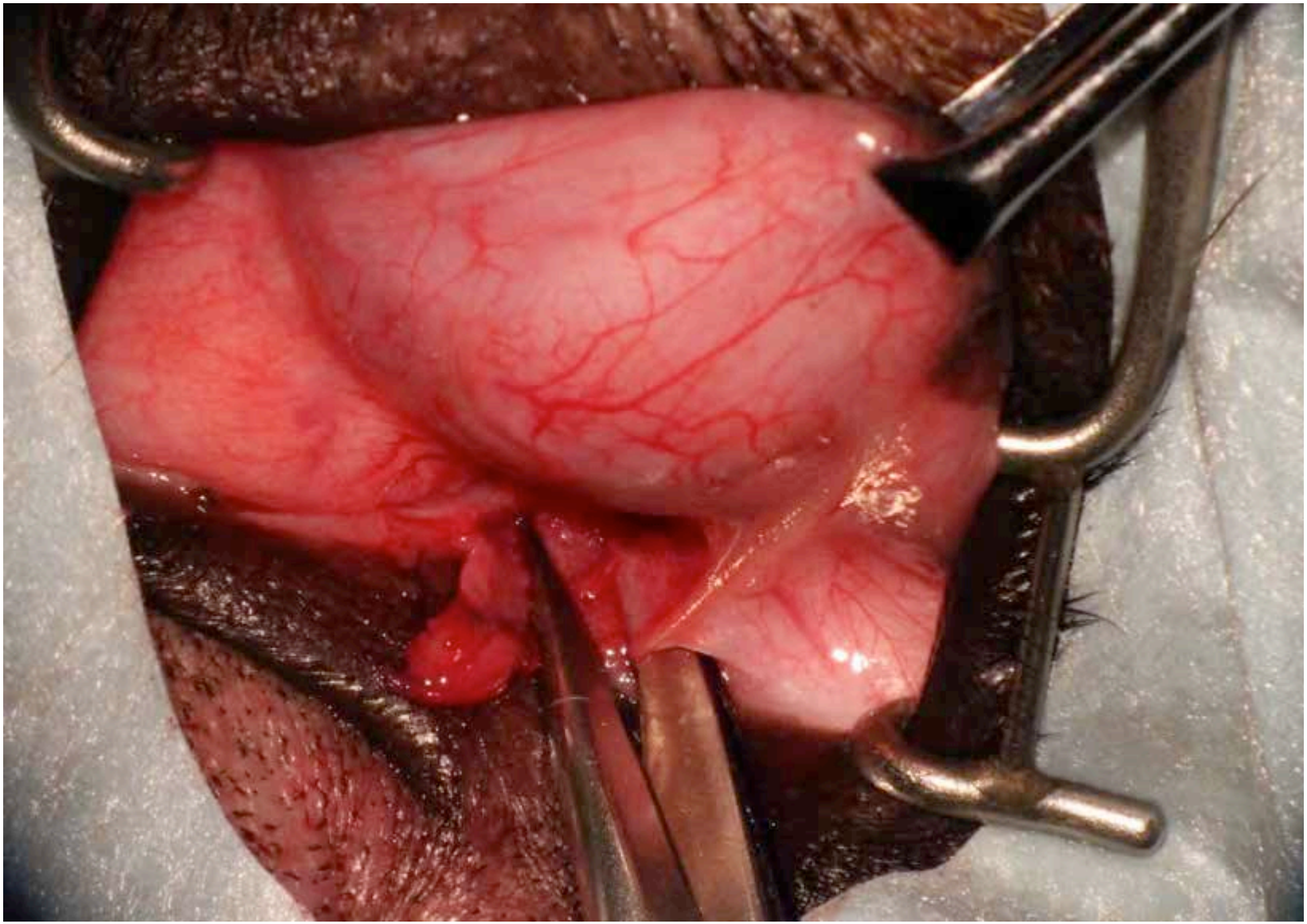
spatulation of the canaliculi – relocation of puncta



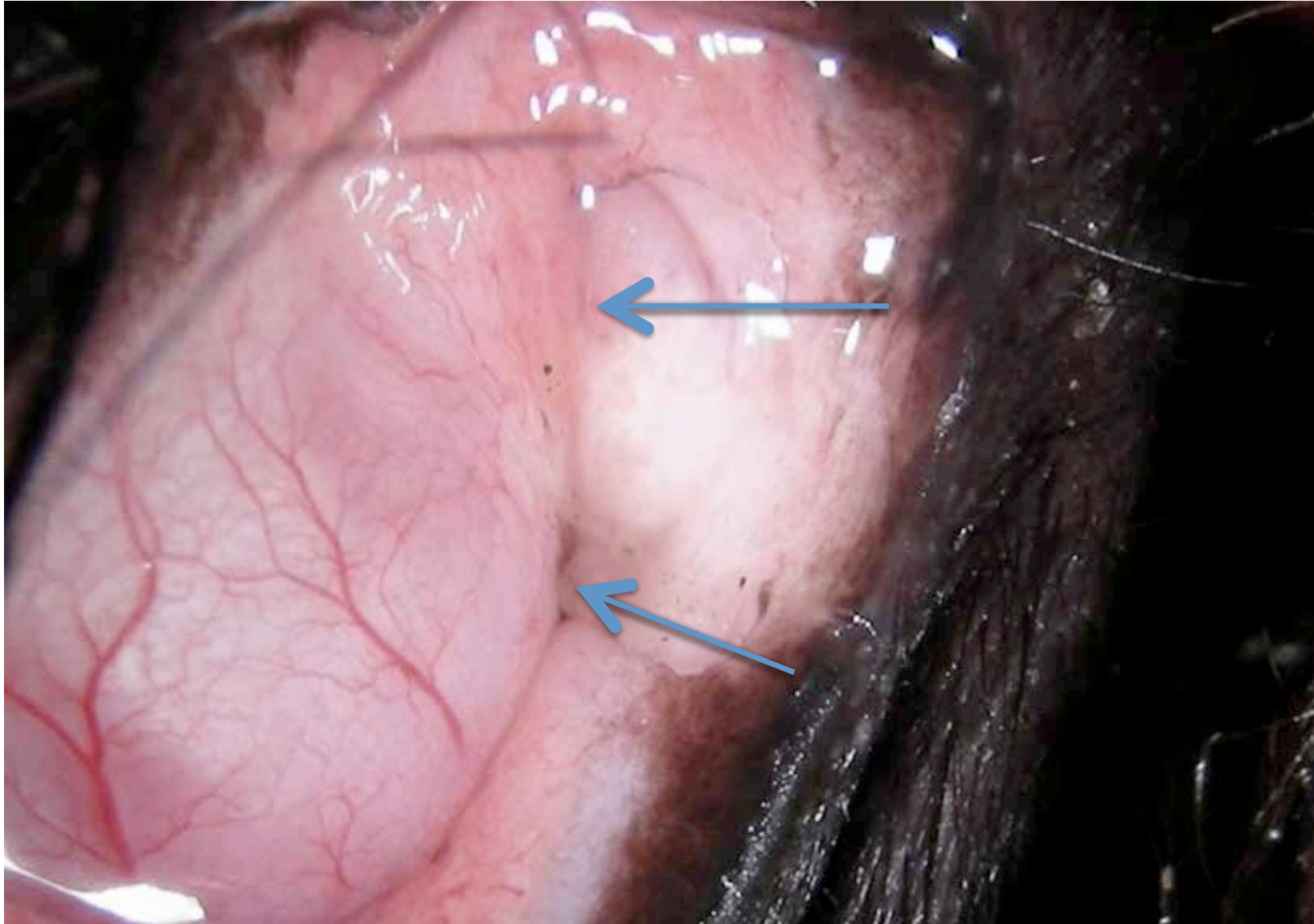




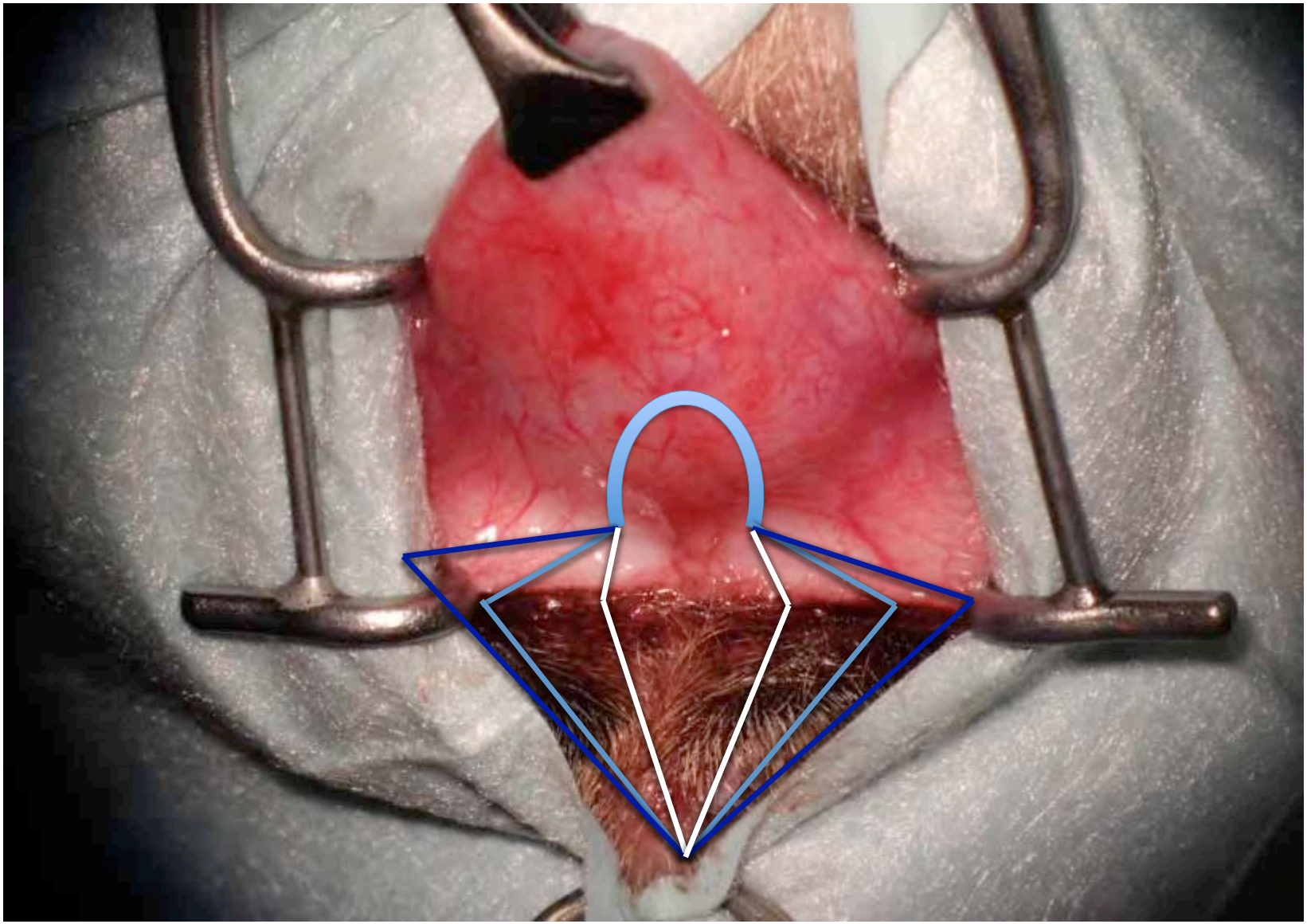




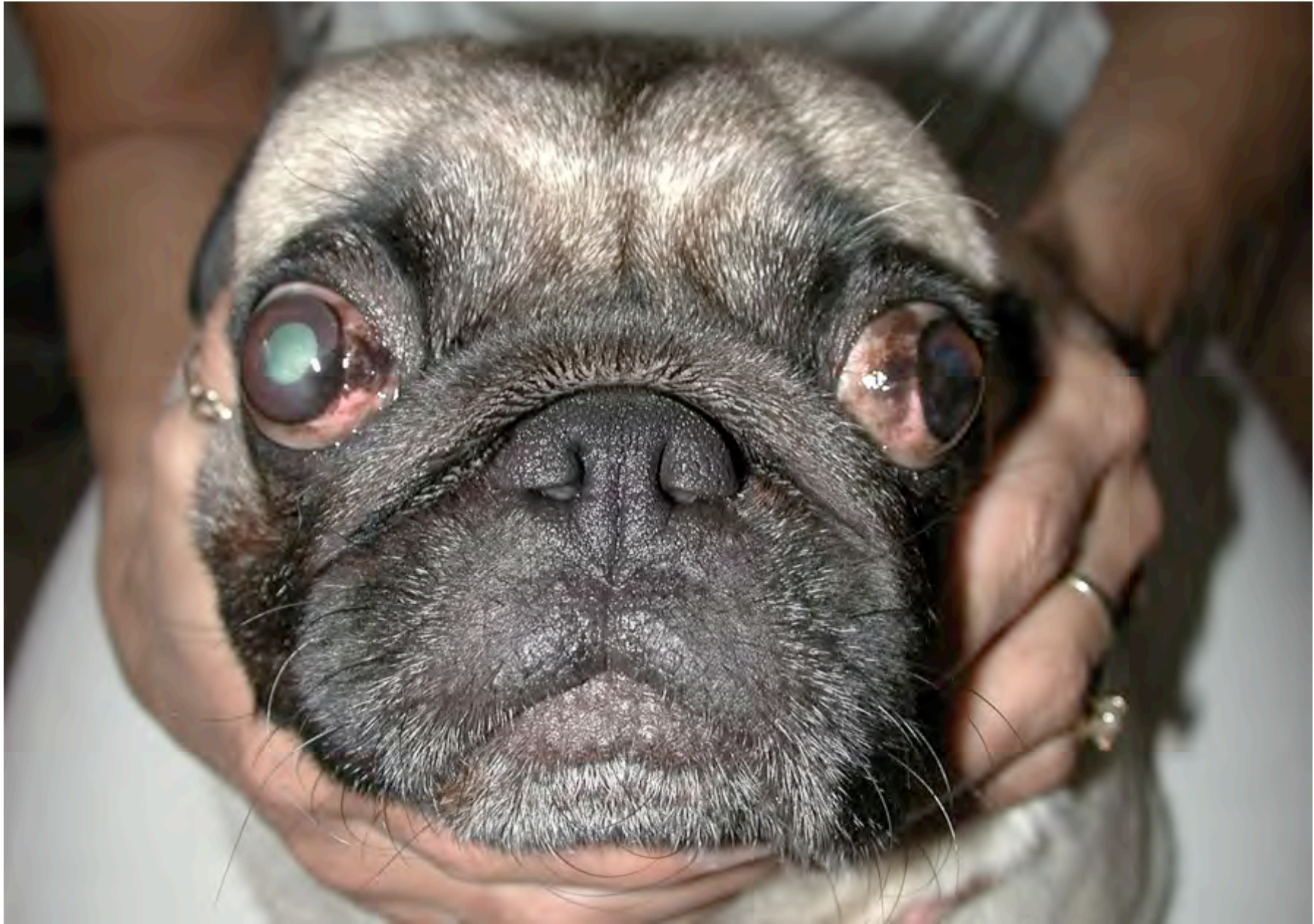10 years post-OP: “relocated” puncta lacrimalia










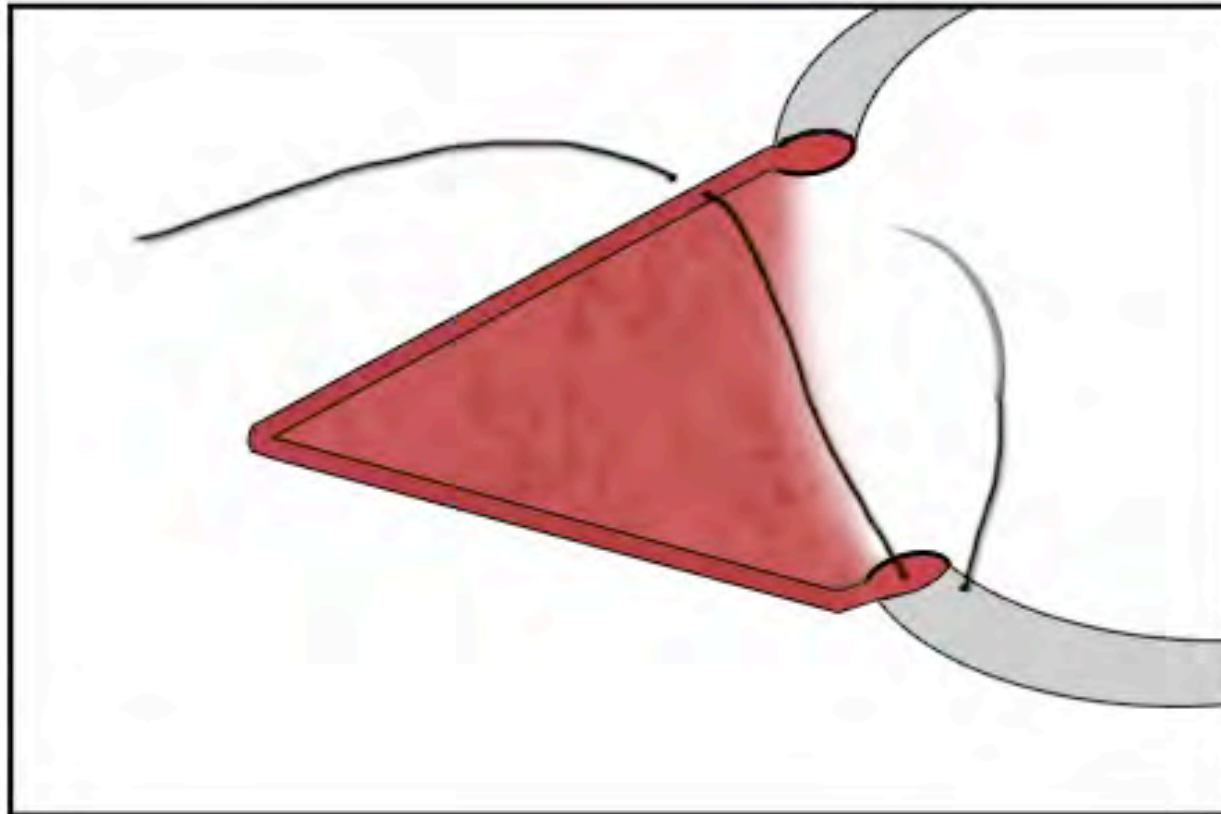


# nasal canthoplasty II



Vicryl® 6-0


# nasal canthoplasty III



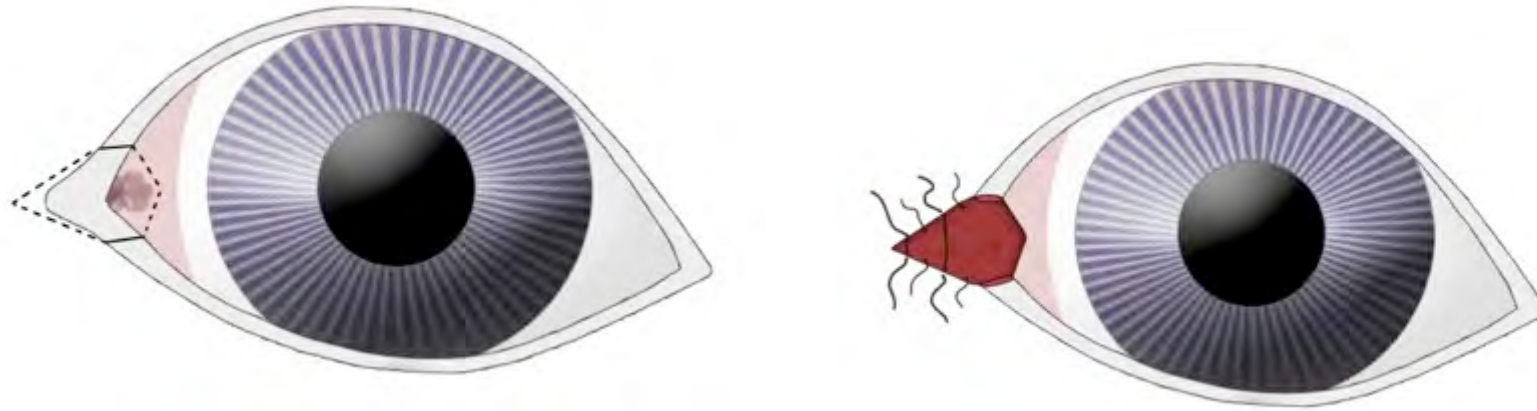
conjunctiva is not sutured



# nasal canthoplasty IV



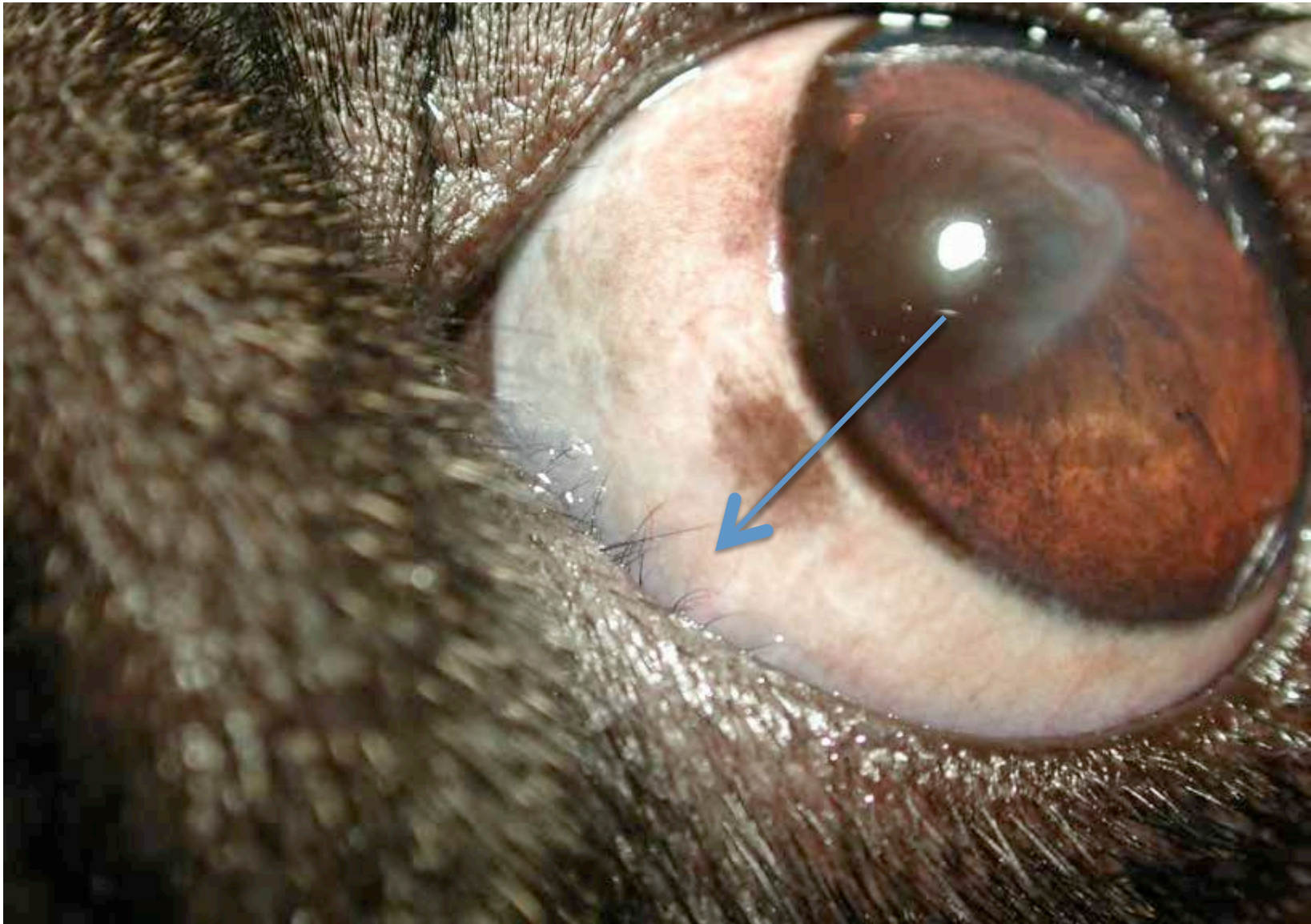
# nasal canthoplasty



**+ lifelong topical therapy in most brachycephalics  
(ciclosporin, tacrolimus etc)**

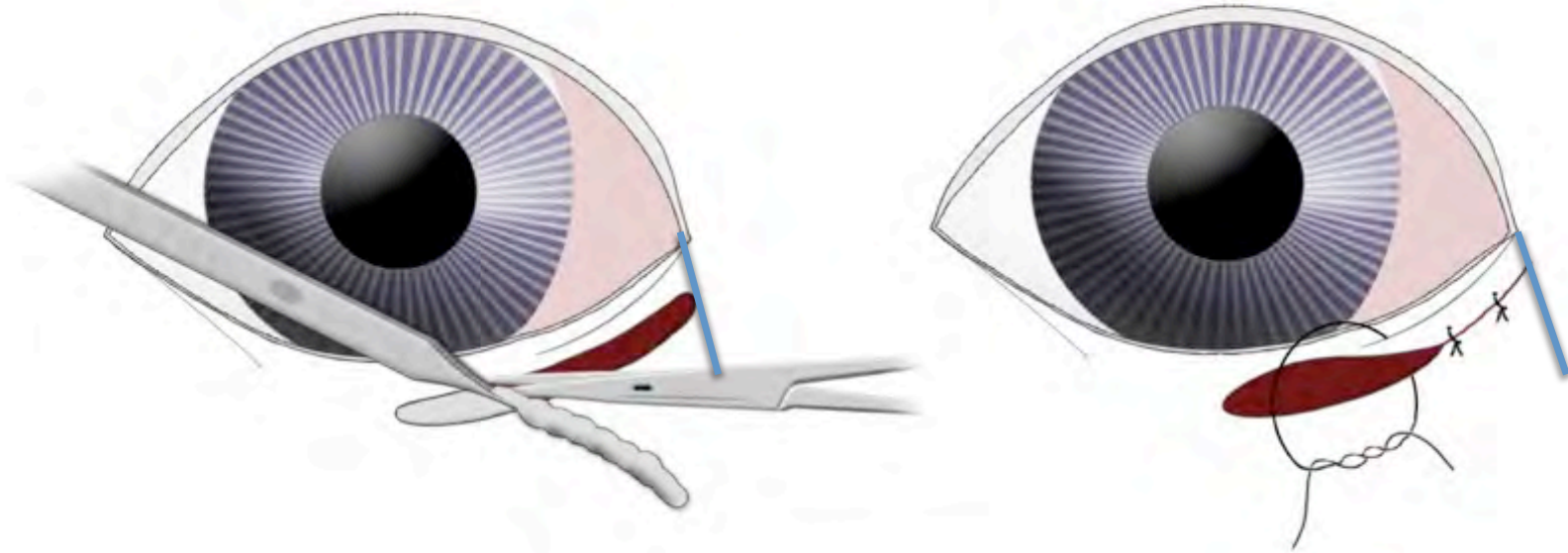
# nasal entropion

- concurrent problem in most pugs
- chronic irritation – trichiasis
- surgical correction is combined with nasal canthoplasty

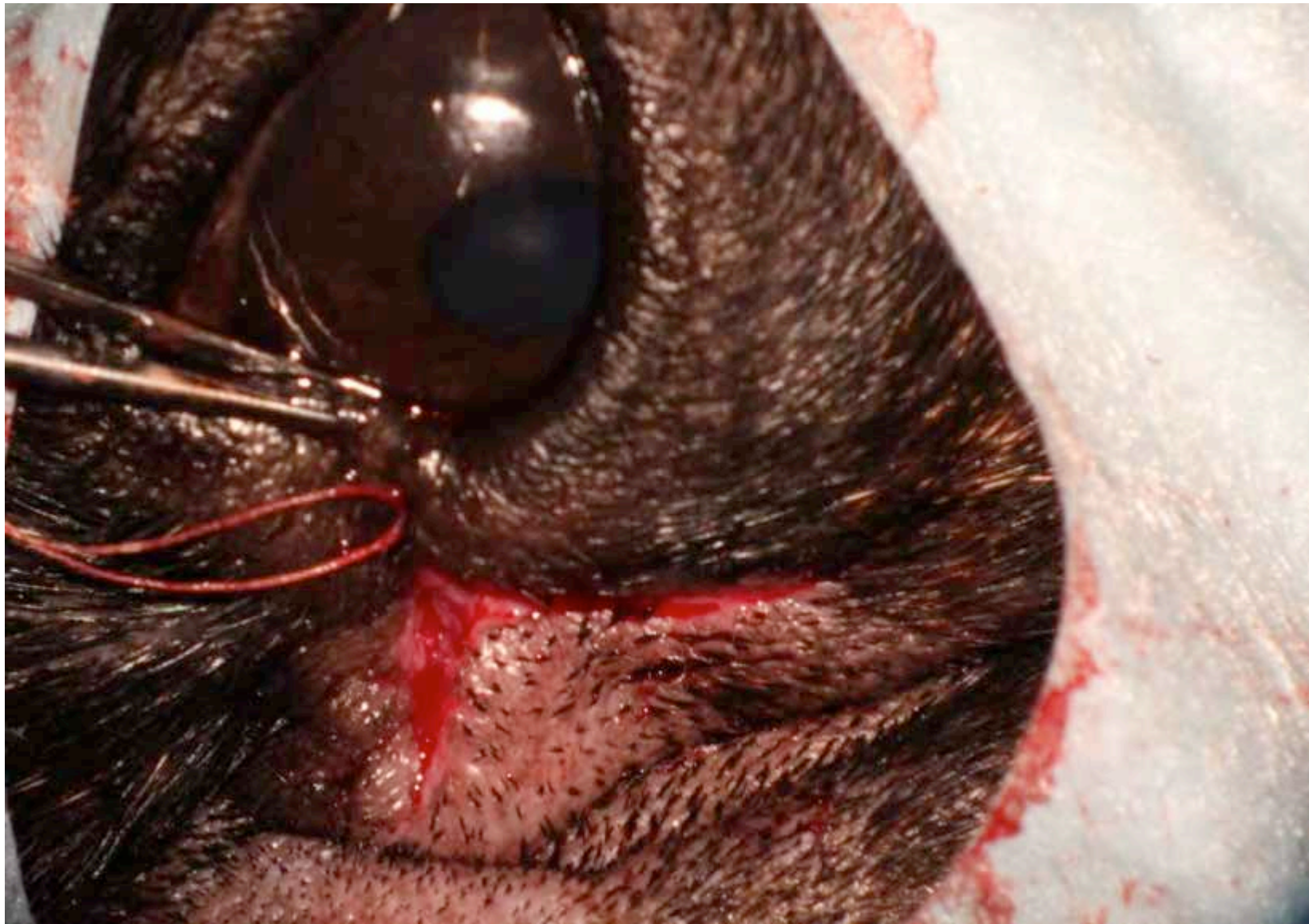

variable degree of nasal entropion

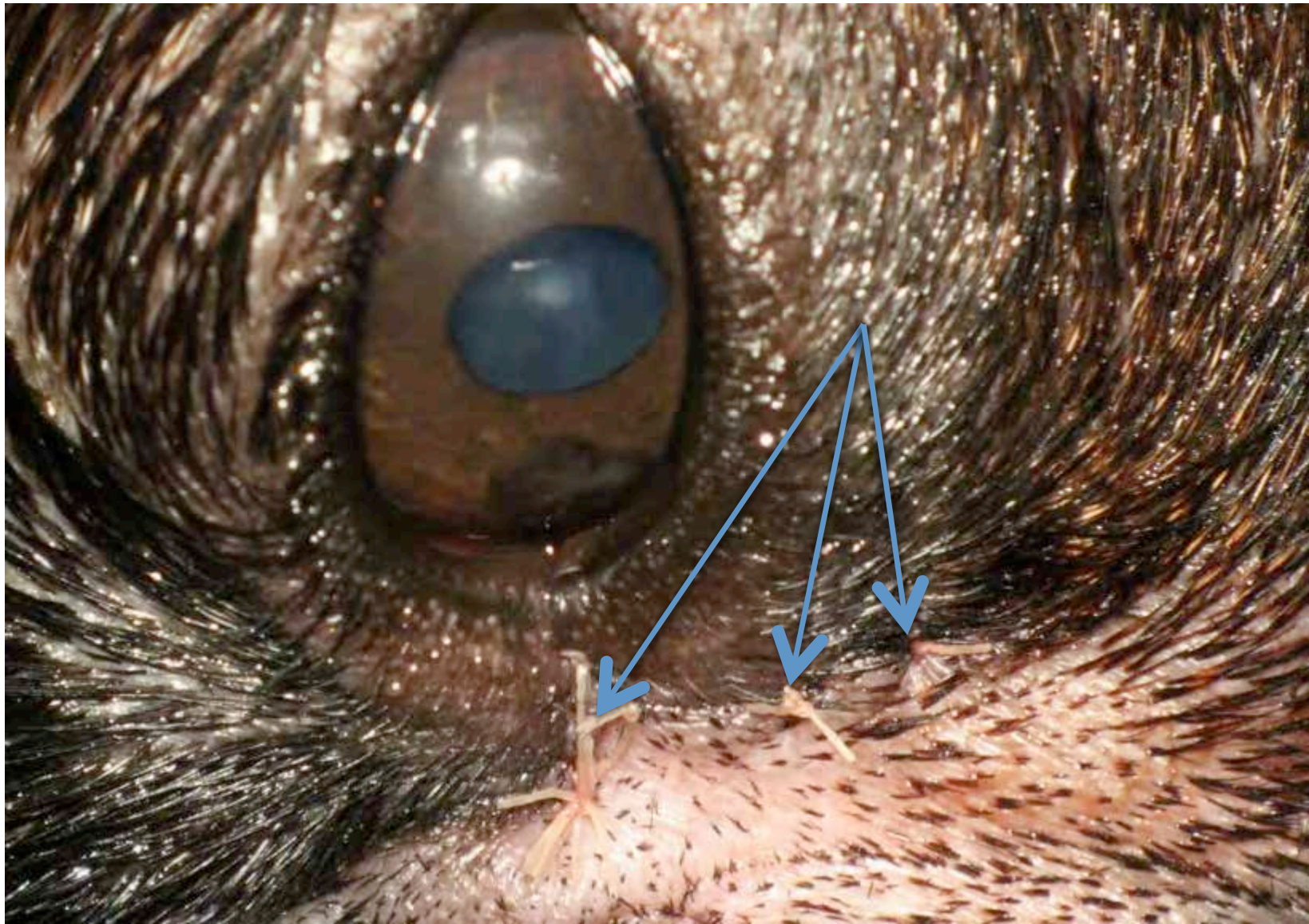
# technique for nasal entropion



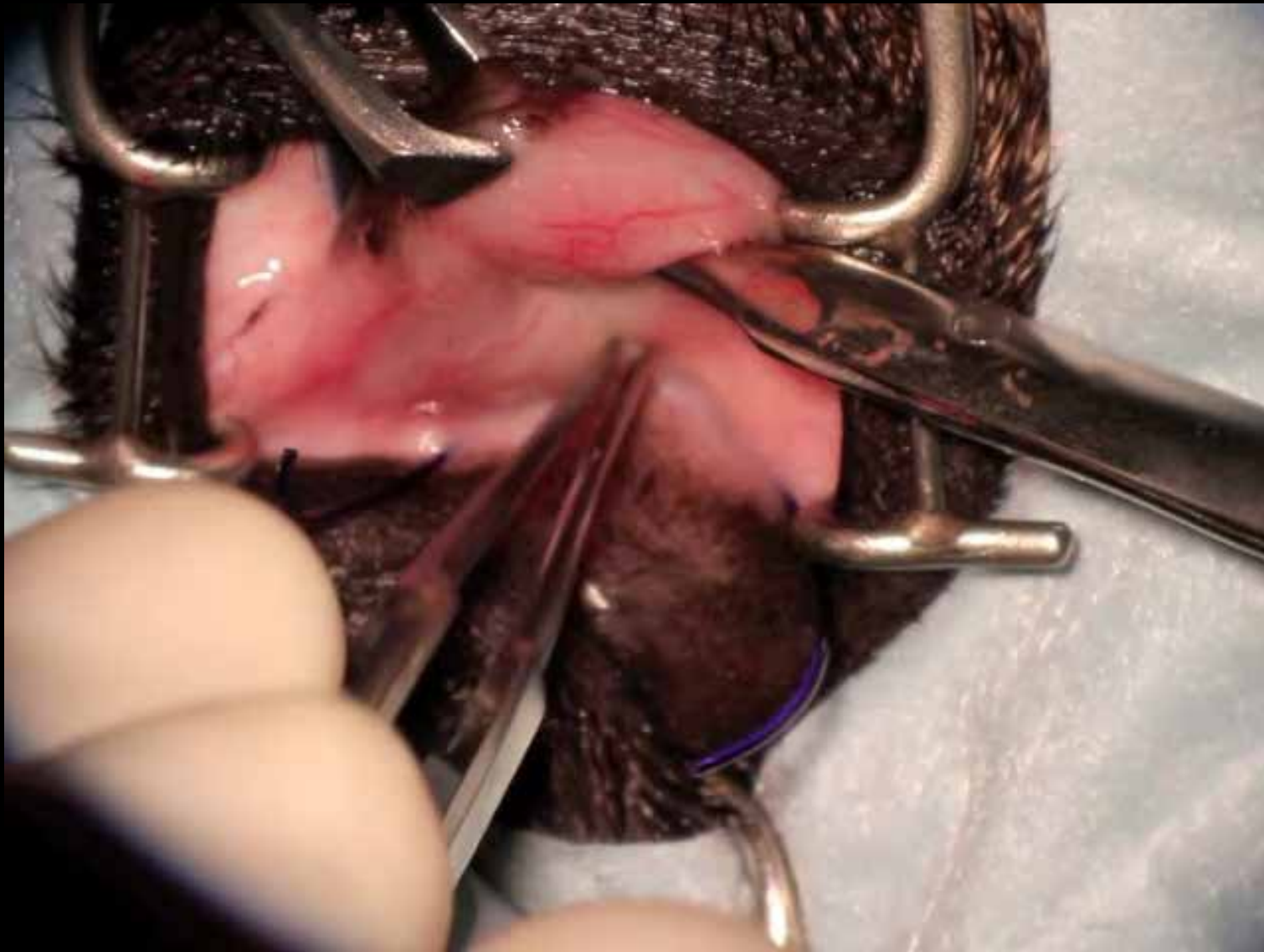






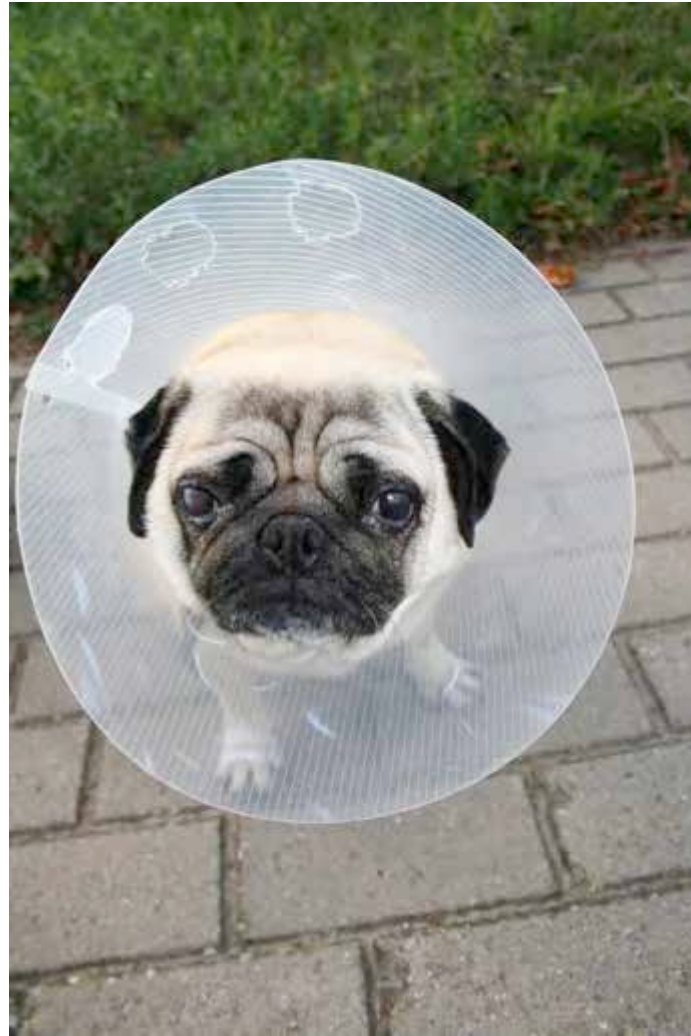
# simplified nasal canthoplasty

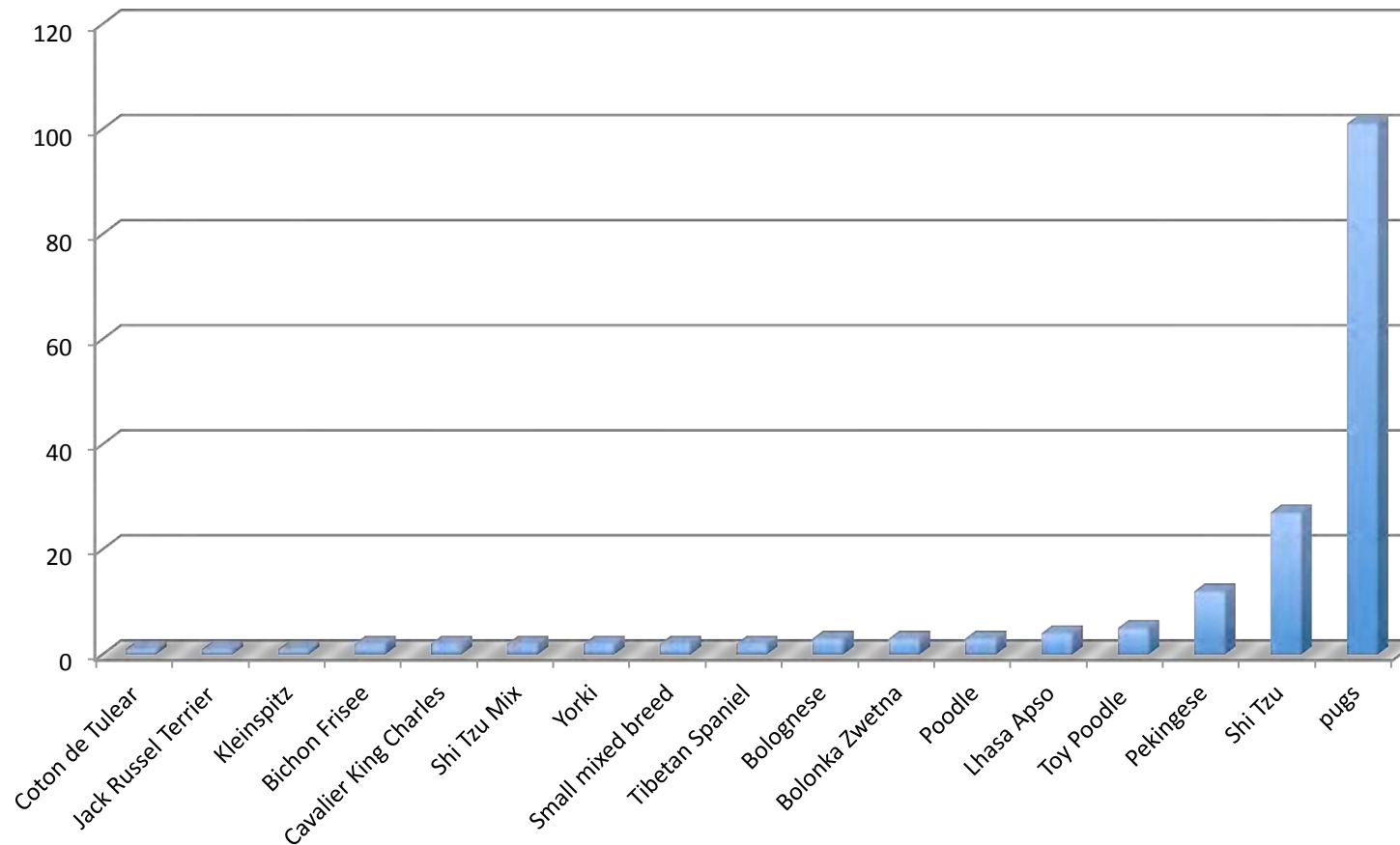




retrospective evaluation (n=173)

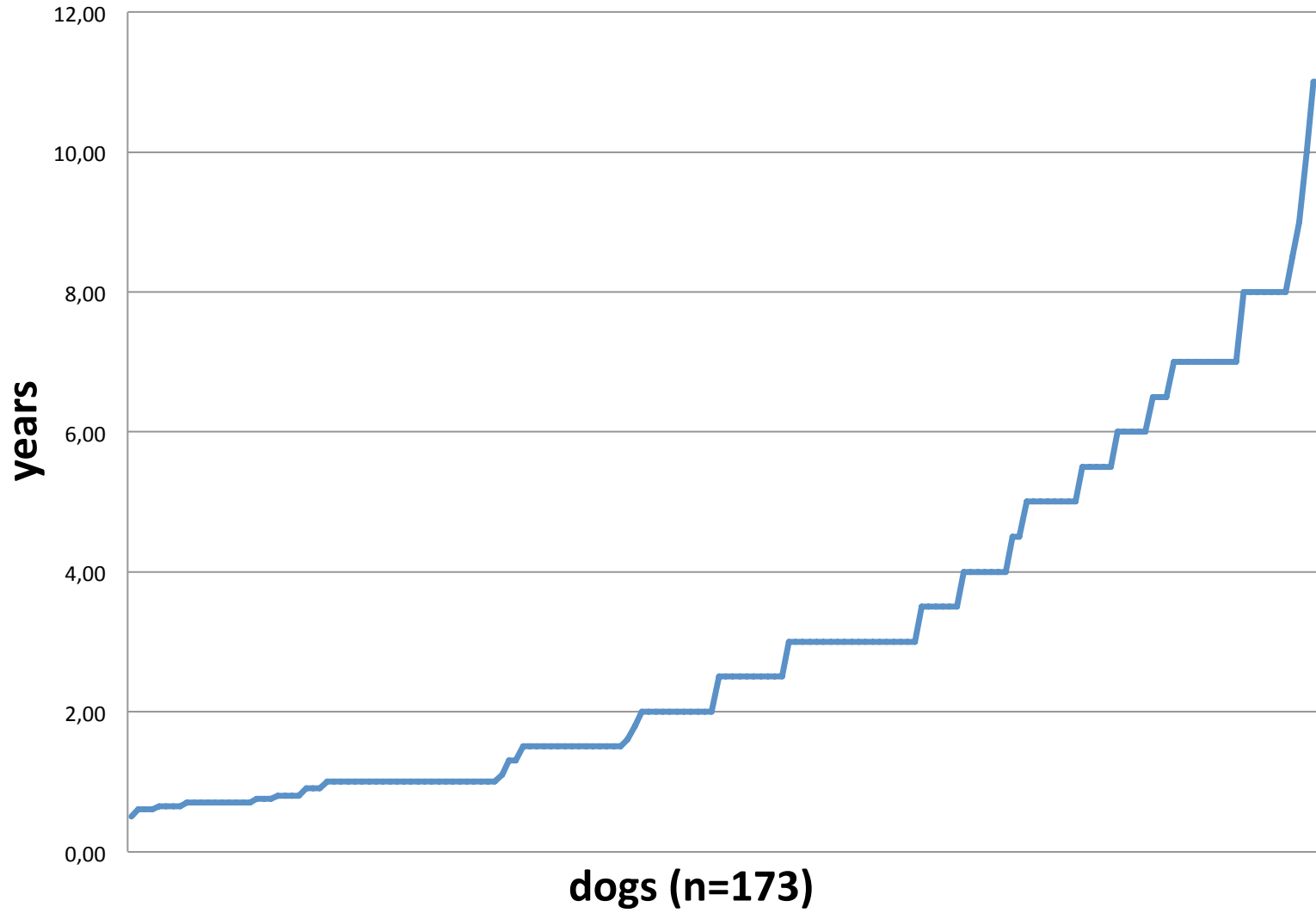


# operated breeds (n=173)



- 101 Pugs, 27 Shih Tzus, 12 Pekingese
- several other breeds

# nasal canthoplasty: age at surgery



mean age at surgery 3,12 years (0,5 – 11 y)



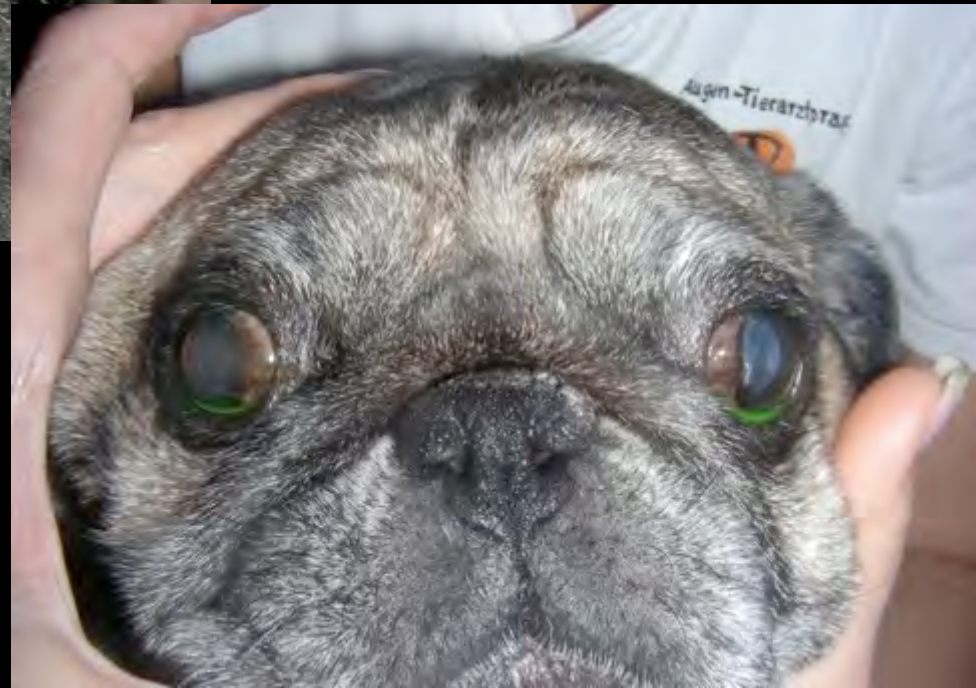# follow up

- no complications related to the technique noted

post-OP nasal canthoplasty: change of facial expression

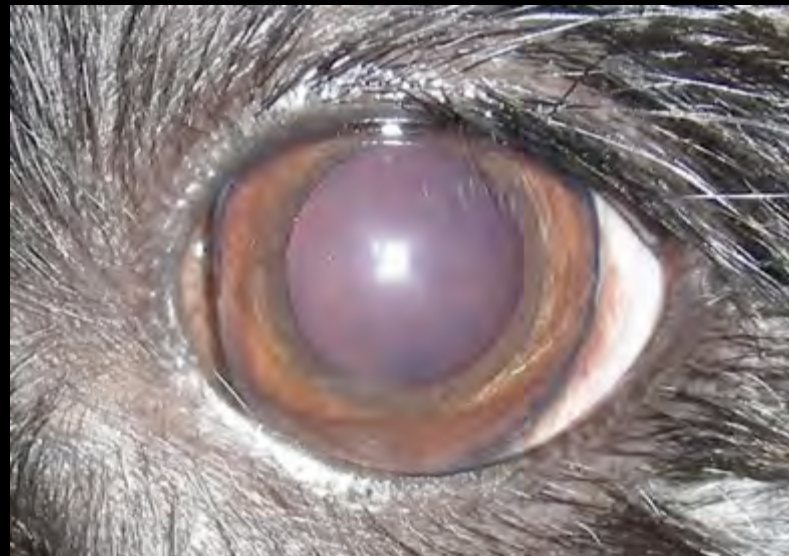

pre-OP



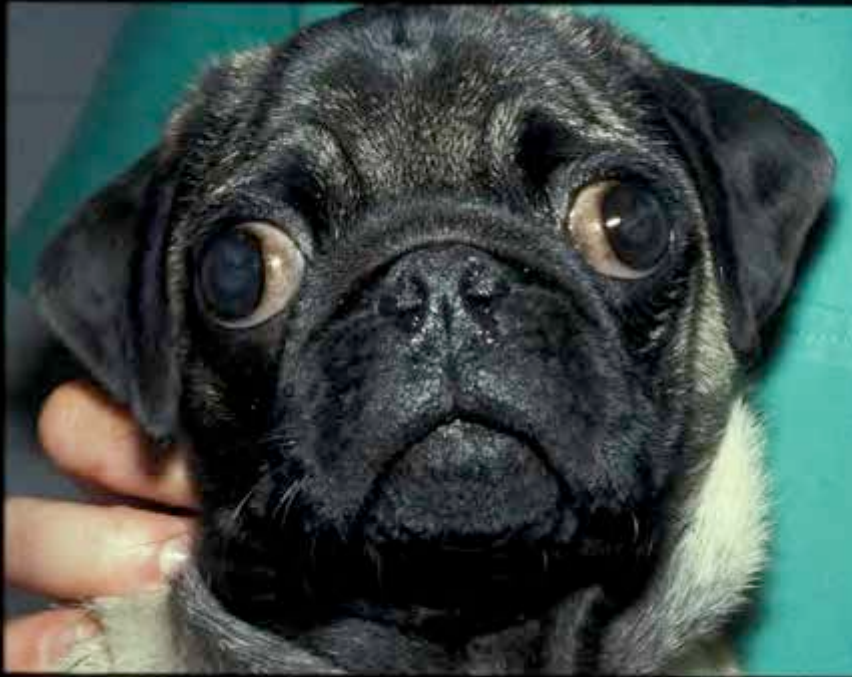post-OP

post-Op: typically rounded nasal canthus

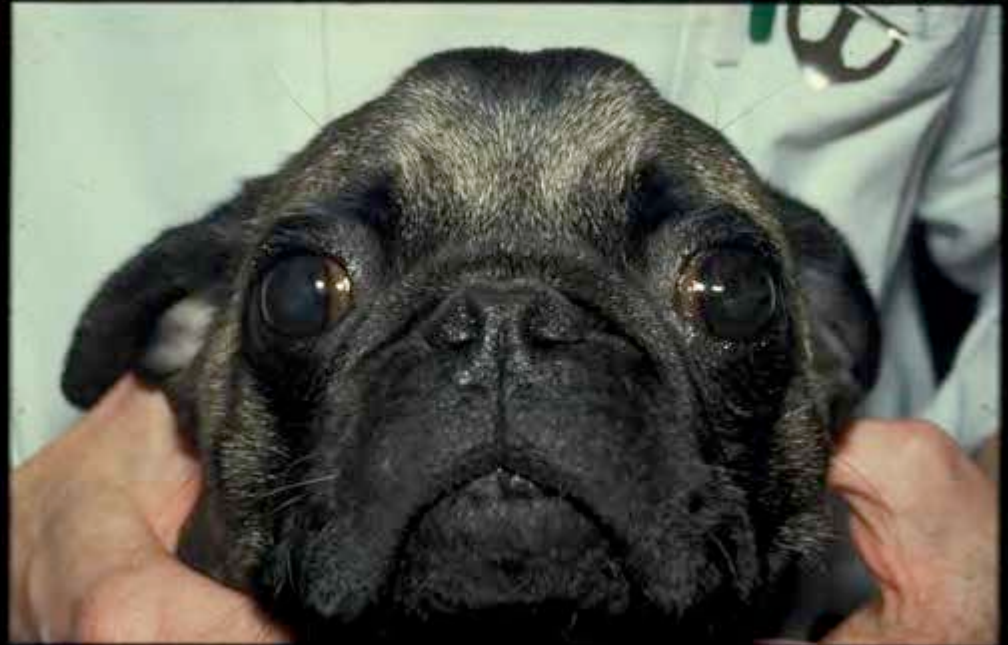



# nasal canthoplasty



pre-OP



post-OP

# nasal canthoplasty



pre-OP

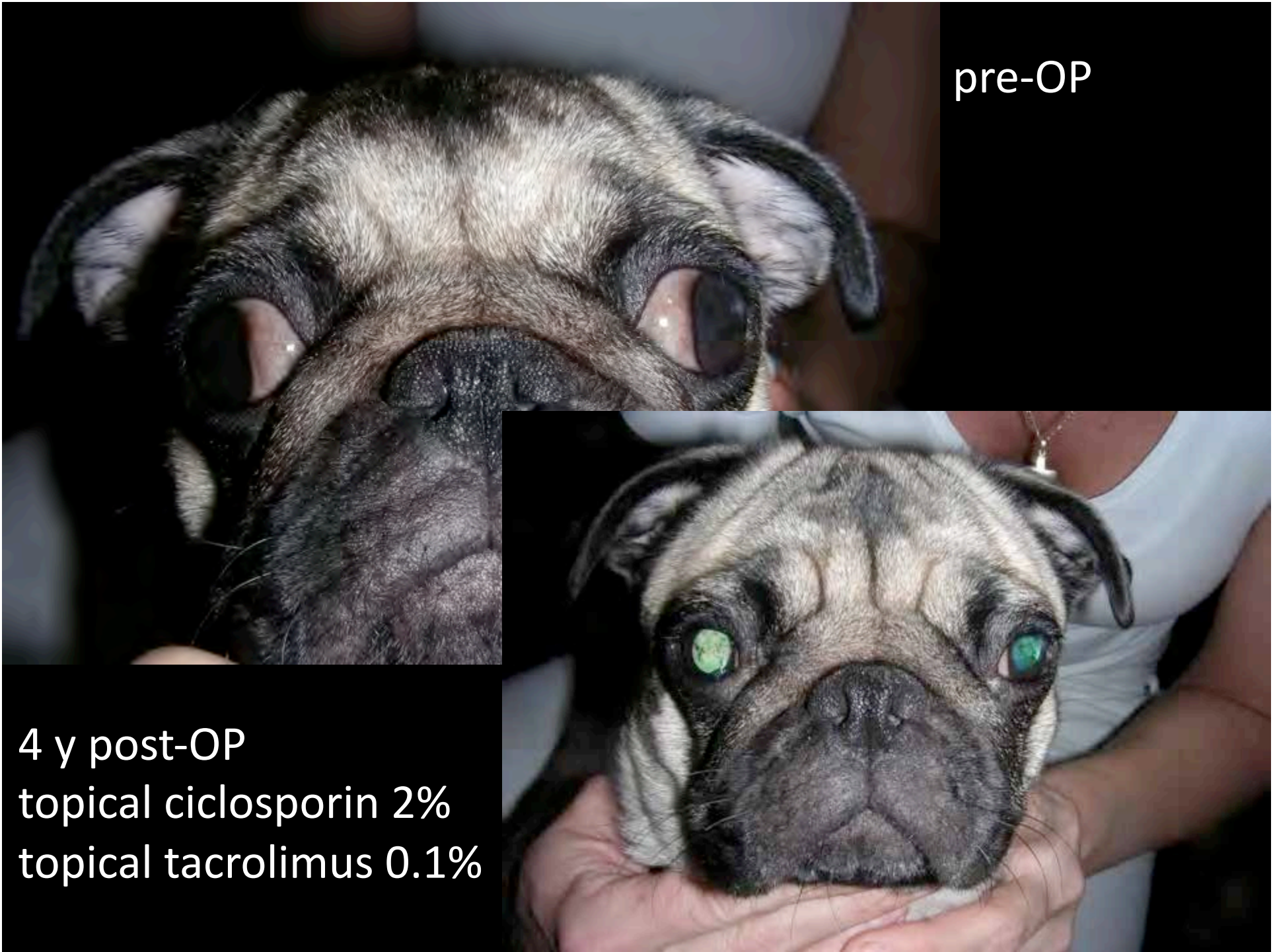


post-OP



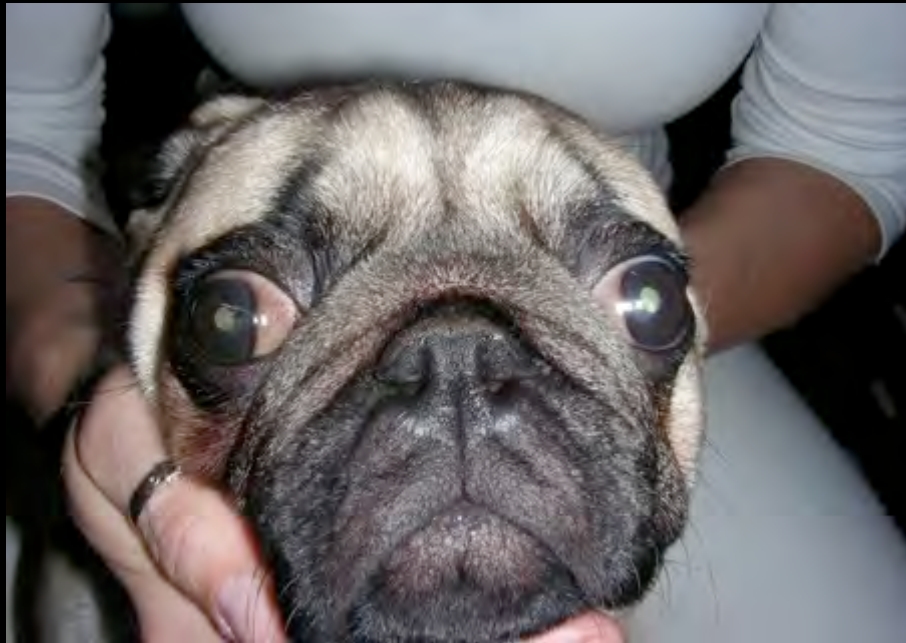pre-OP

4 y post-OP  
topical ciclosporin 2%  
topical tacrolimus 0.1%





nasal canthoplasty + topical ciclosporin 2%



pre-OP

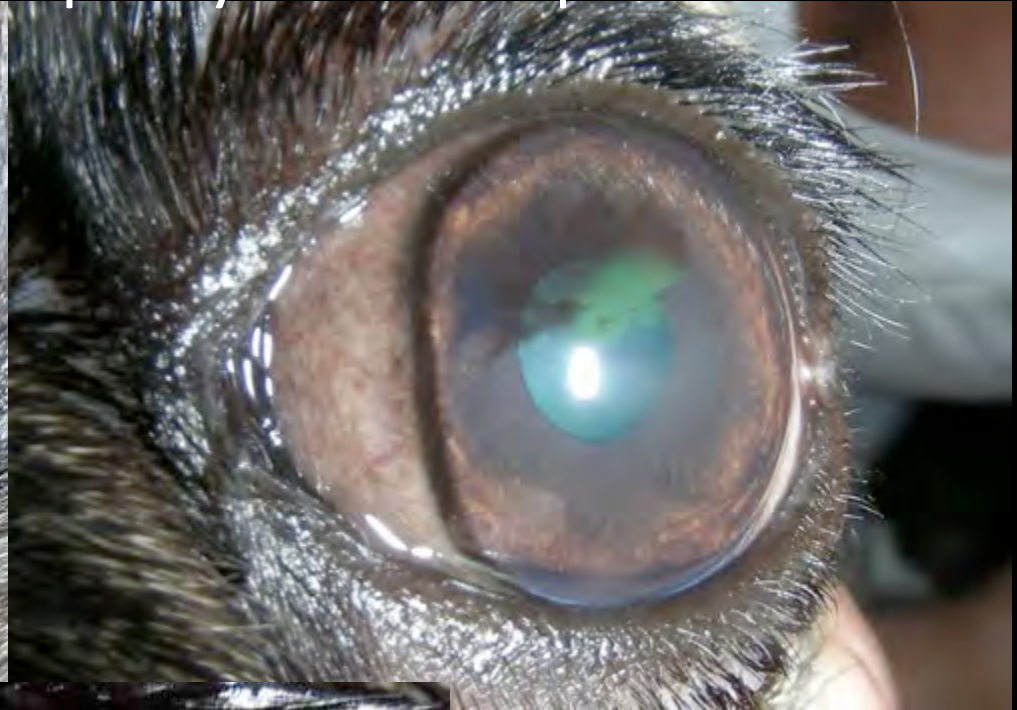
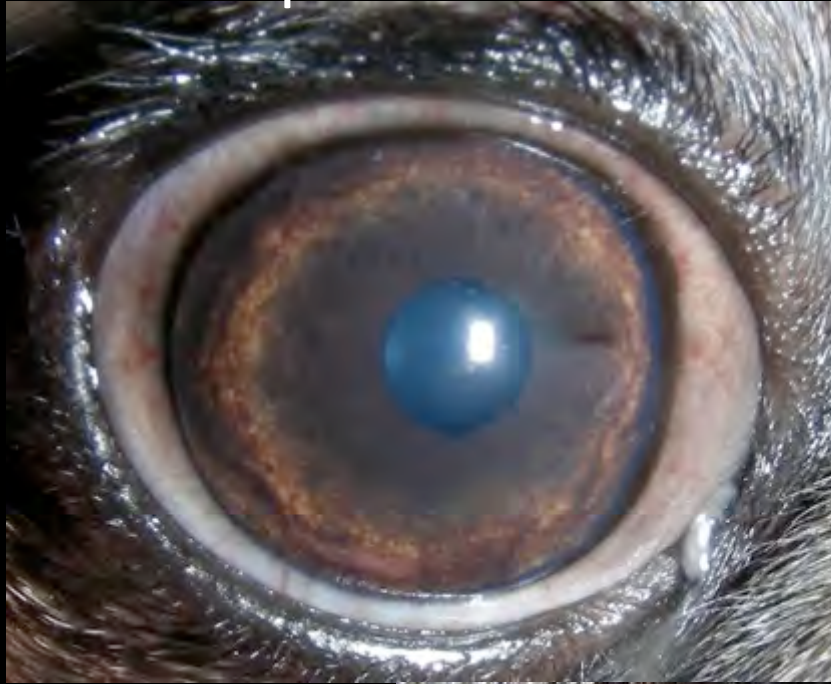
post OP



4 y post-OP

pre-OP nasal canthoplasty and ciclosporine 2%

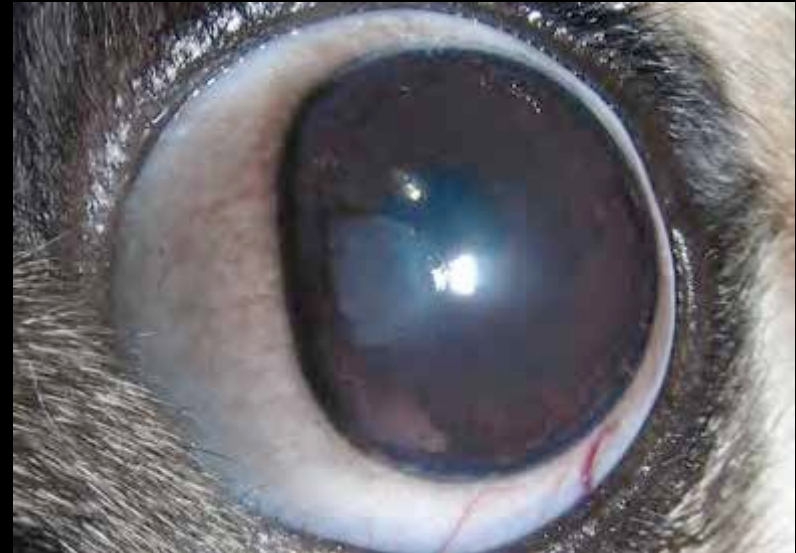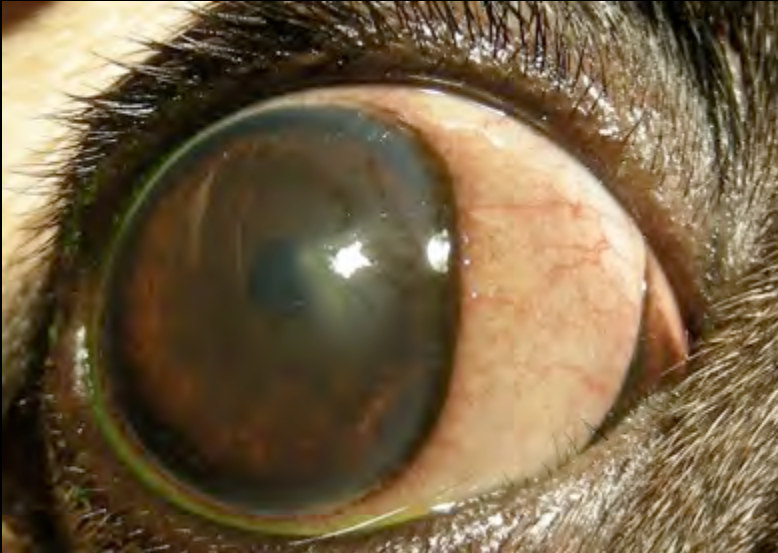


3 y post-OP

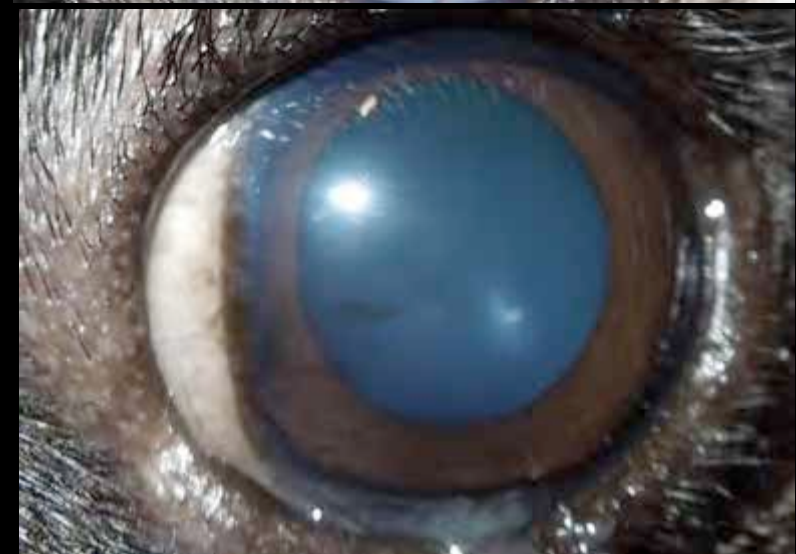

# nasal canthoplasty + topical ciclosporin 2%

pre-OP



4 y post-OP

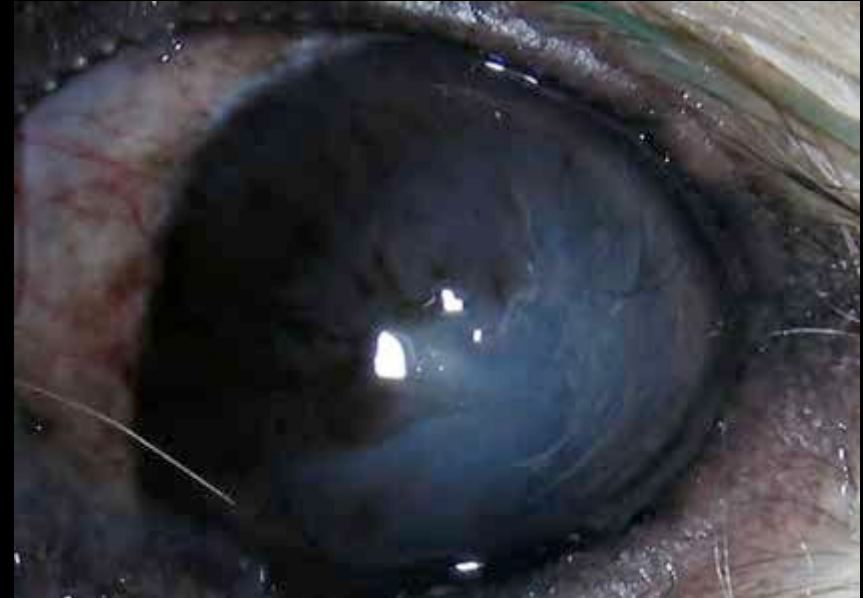
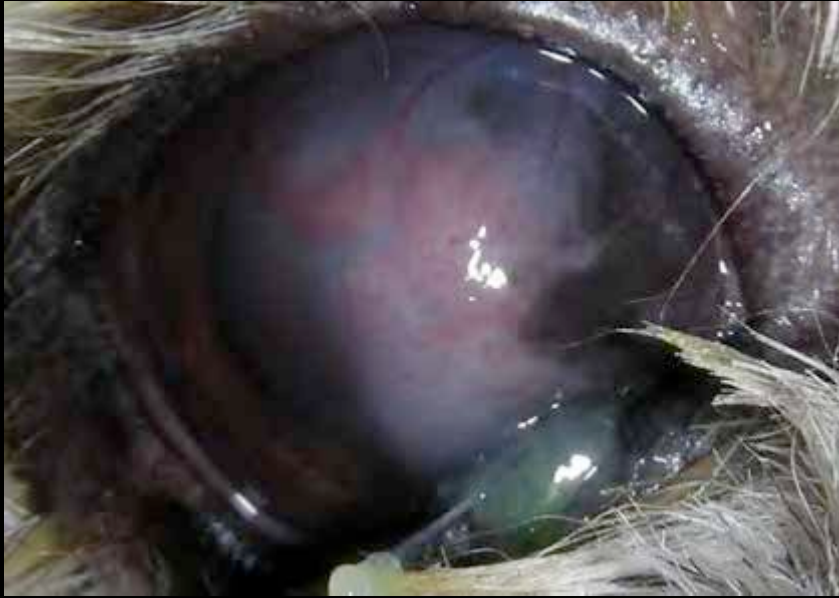


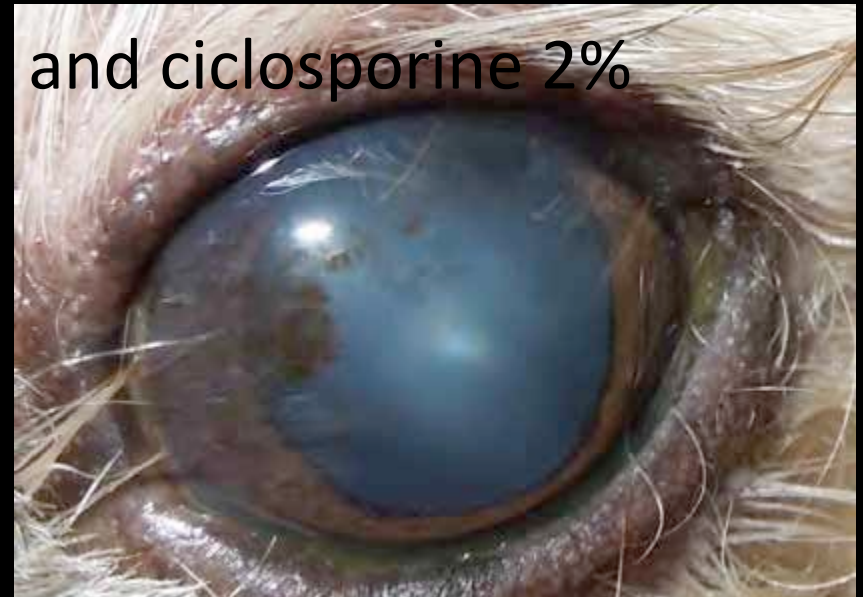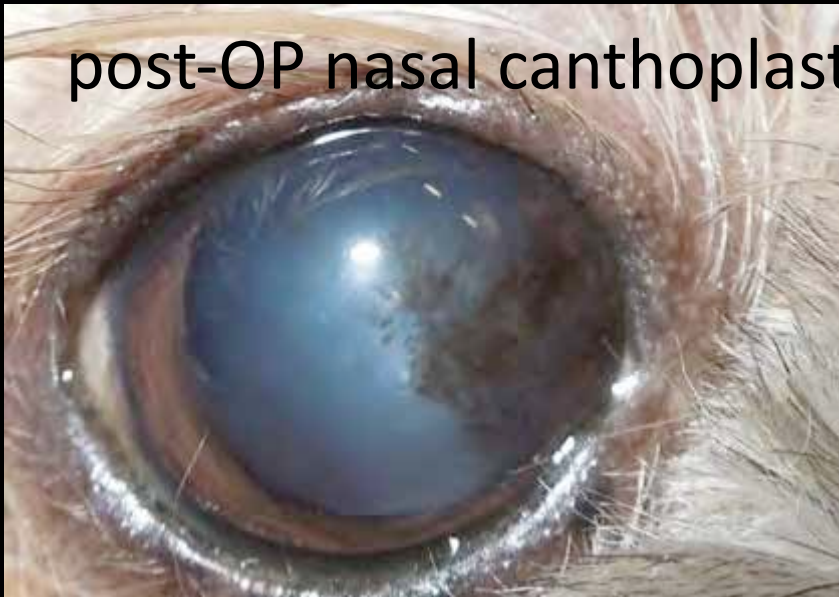Labelle et al: Prevalence and risk factors for the development of pigmentary keratitis in the pug  
Proc. ACVO 2012

- PK in 80 % of the dogs examined (n=295)
- statistical evaluation of risk factors
  - STT, TFBUT, CCT, entropion etc – not significantly associated

pre-OP nasal canthoplasty



post-OP nasal canthoplasty and ciclosporine 2%



# lagophthalmus and nasal fold trichiasis

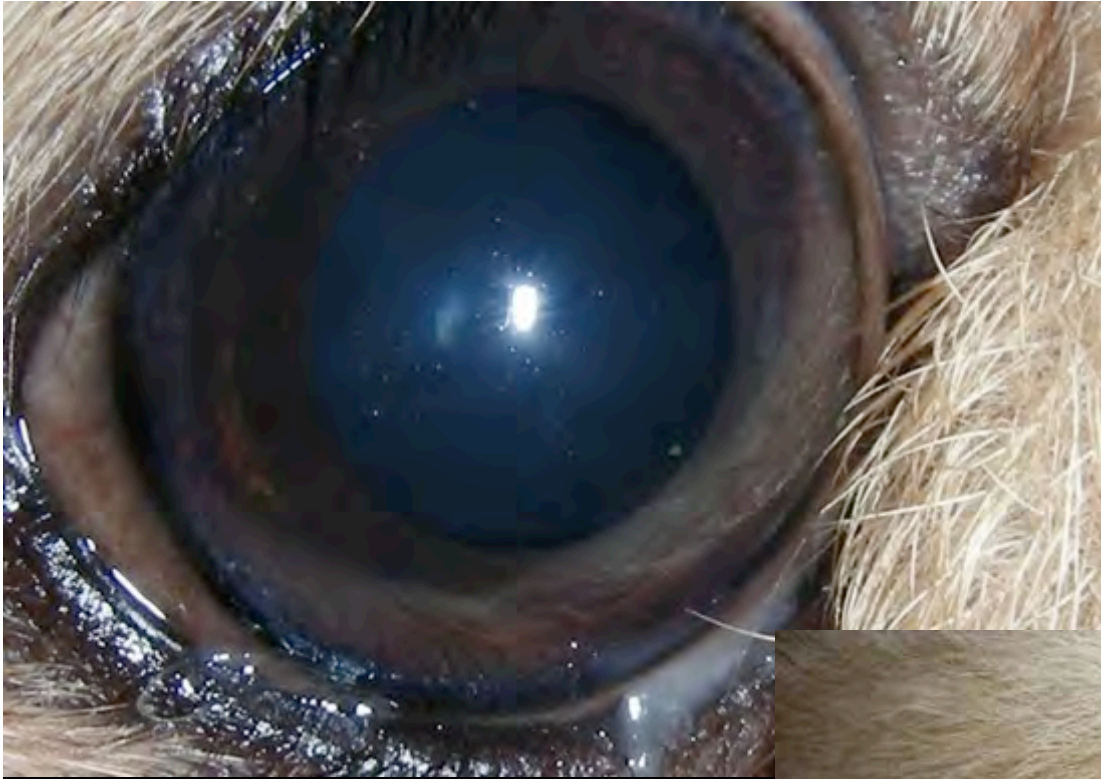

pre-OP canthoplasty

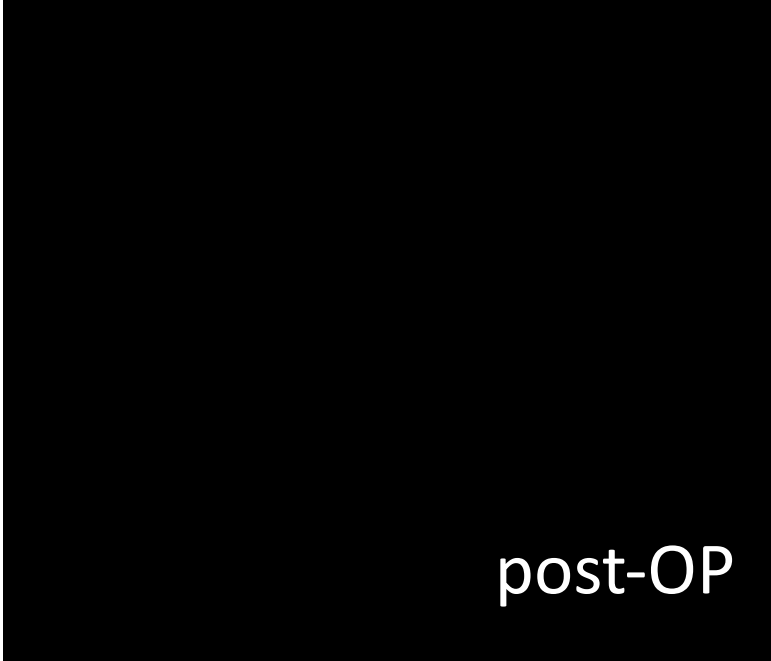

post-OP

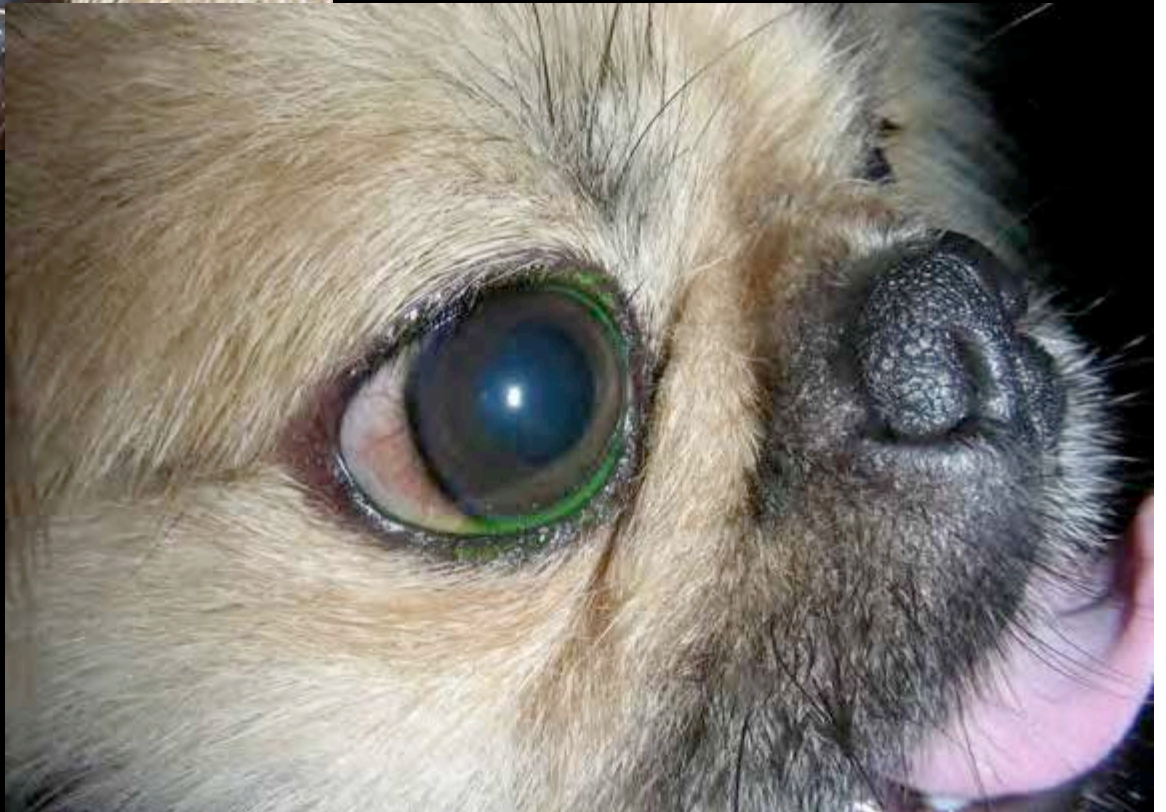



pre-OP

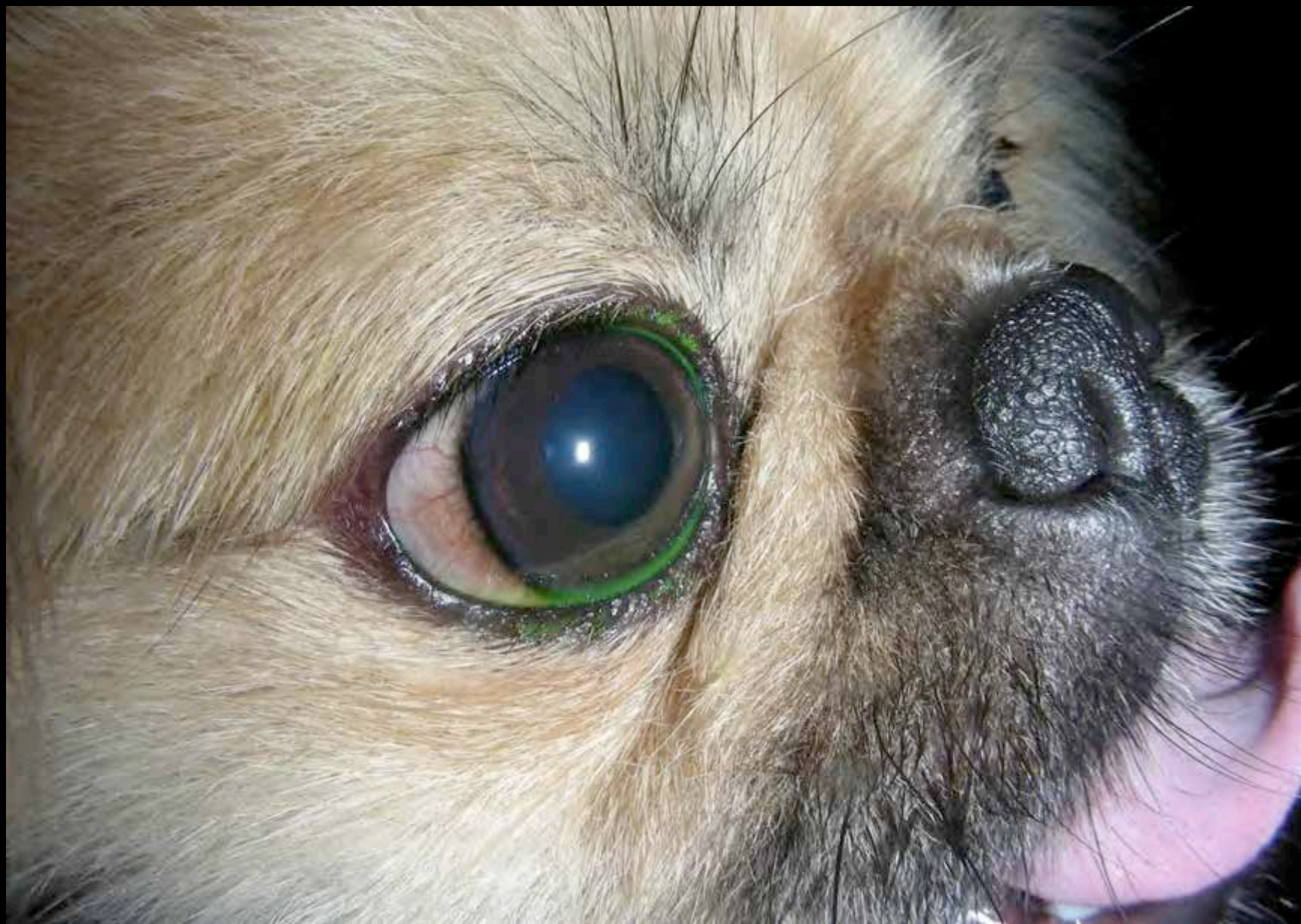

post-OP





post-OP nasal canthoplasty





post-OP nasal canthoplasty



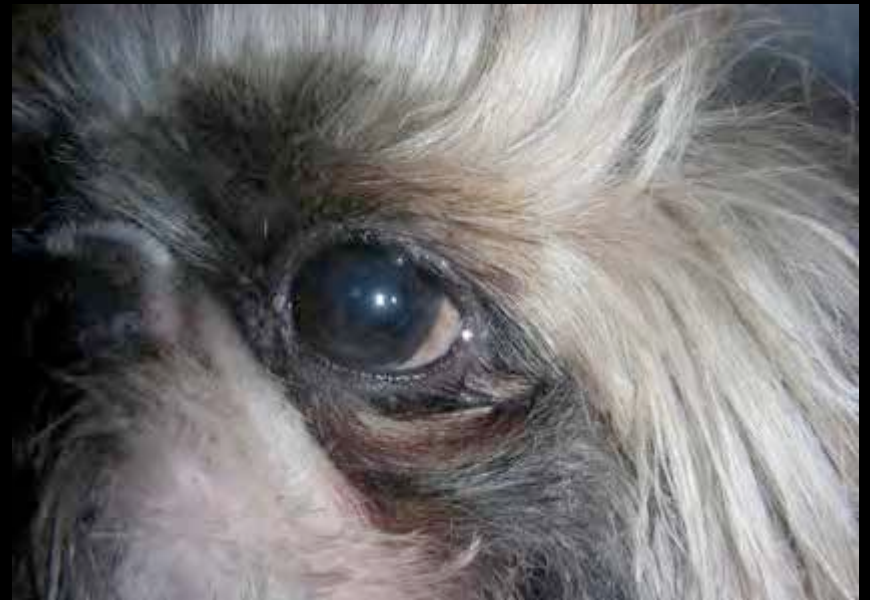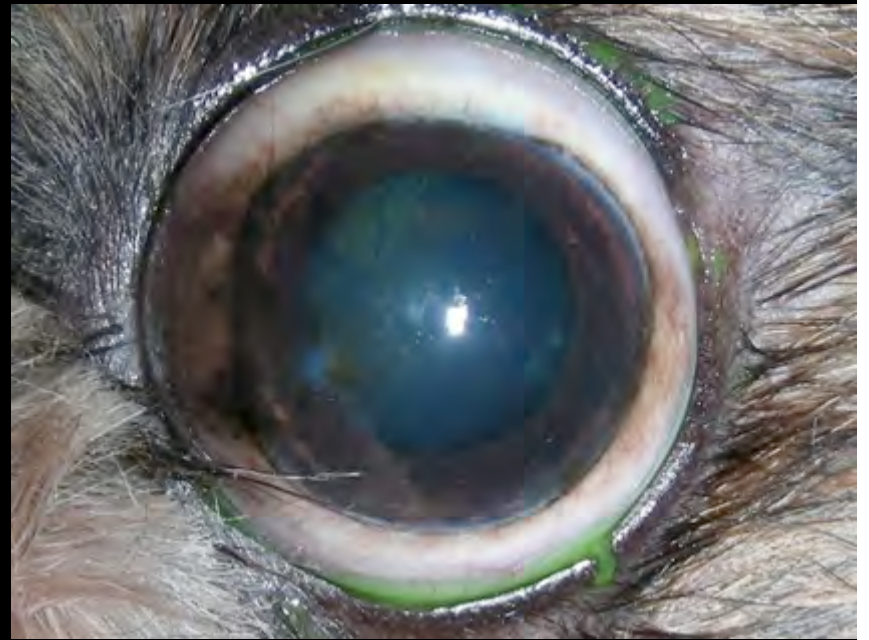

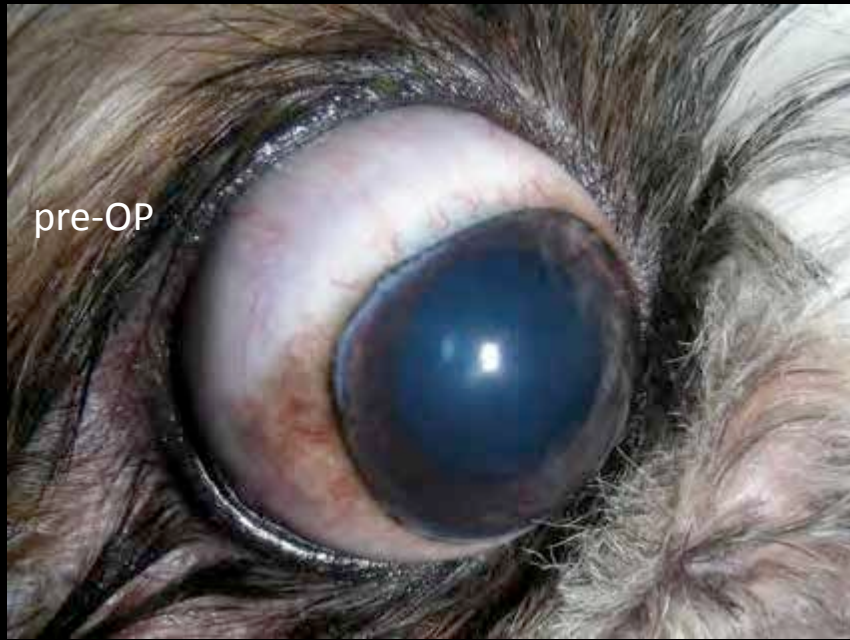


pre-OP



post-OP







pre-OP nasal canthoplasty



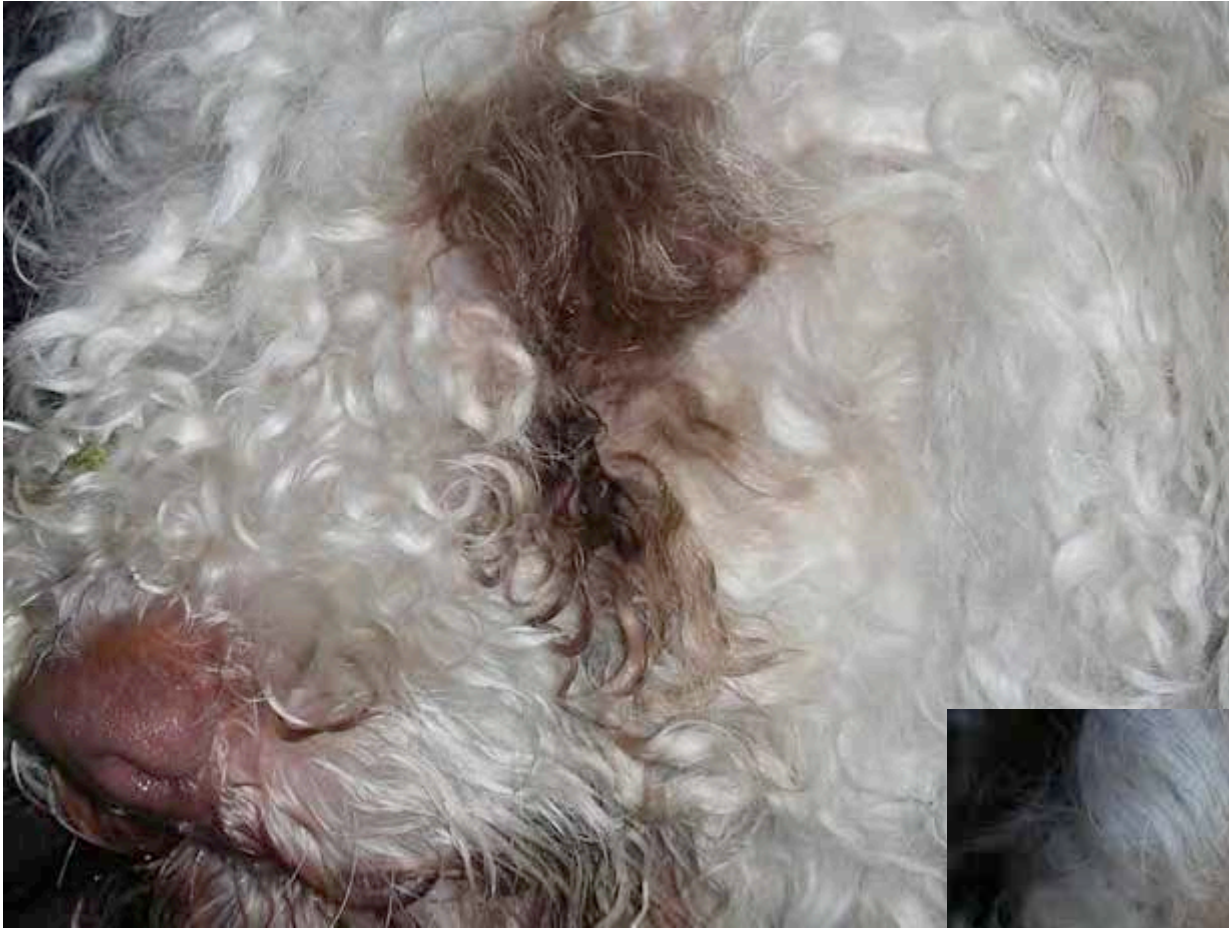post-OP nasal canthoplasty





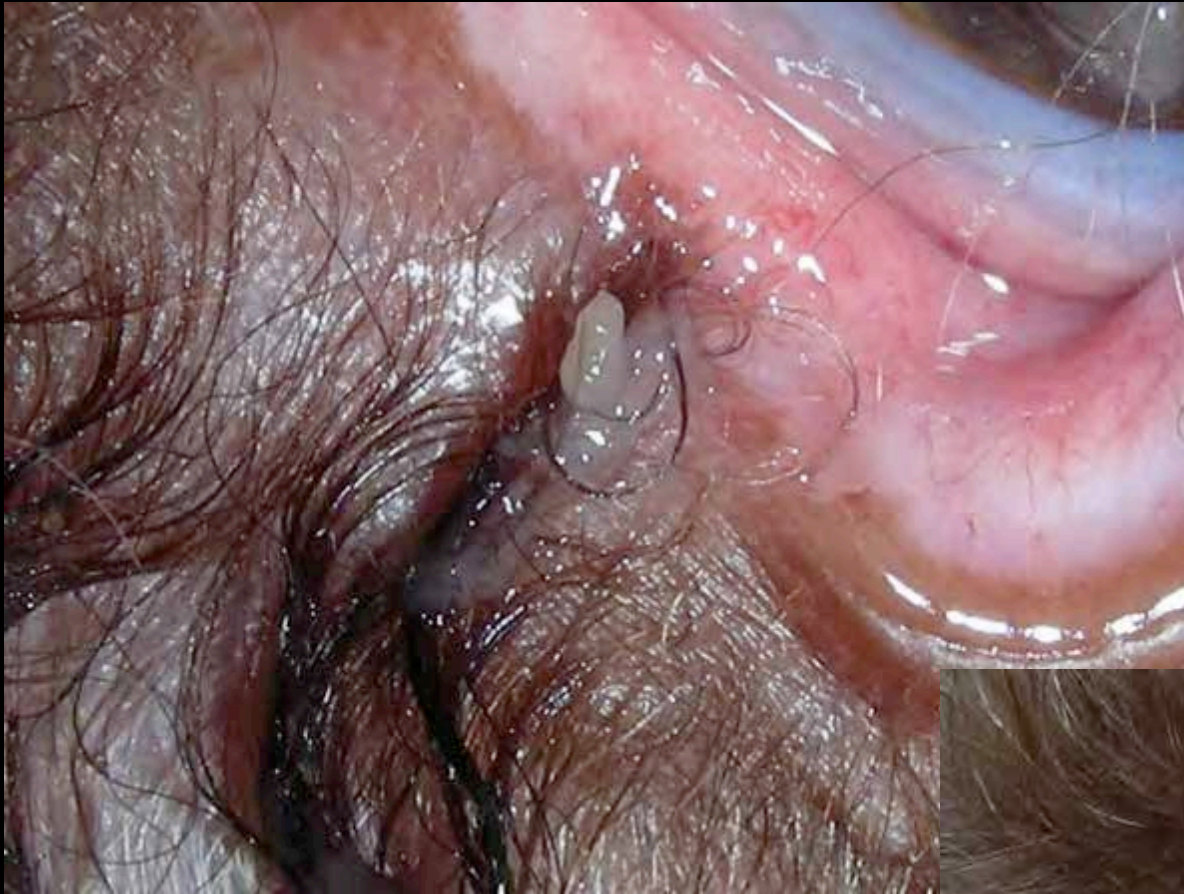

pre-OP

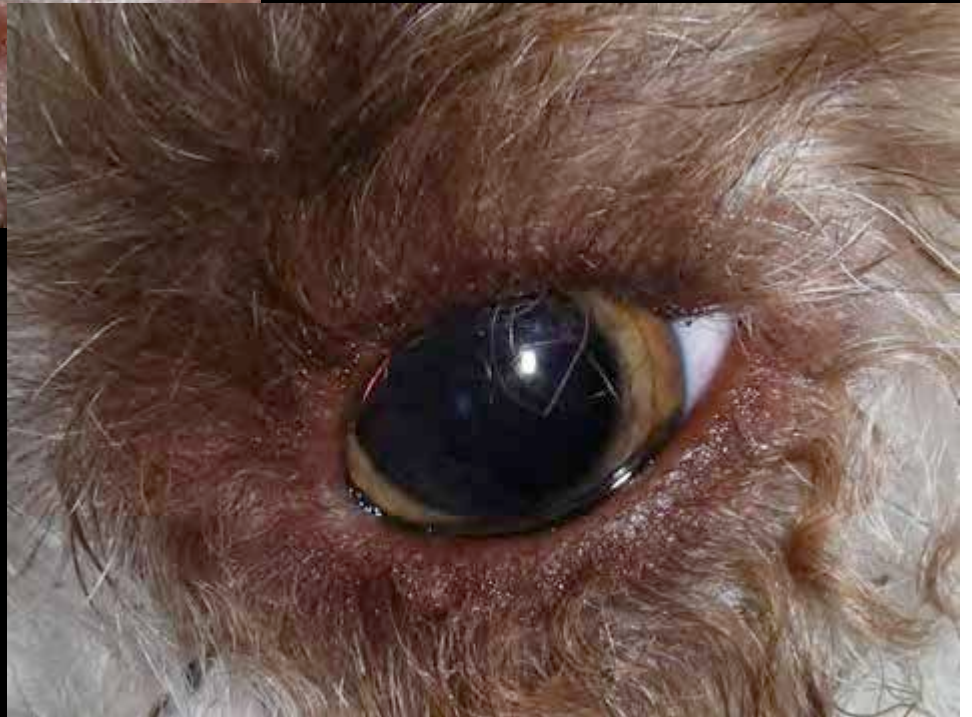

post-OP

pre-OP

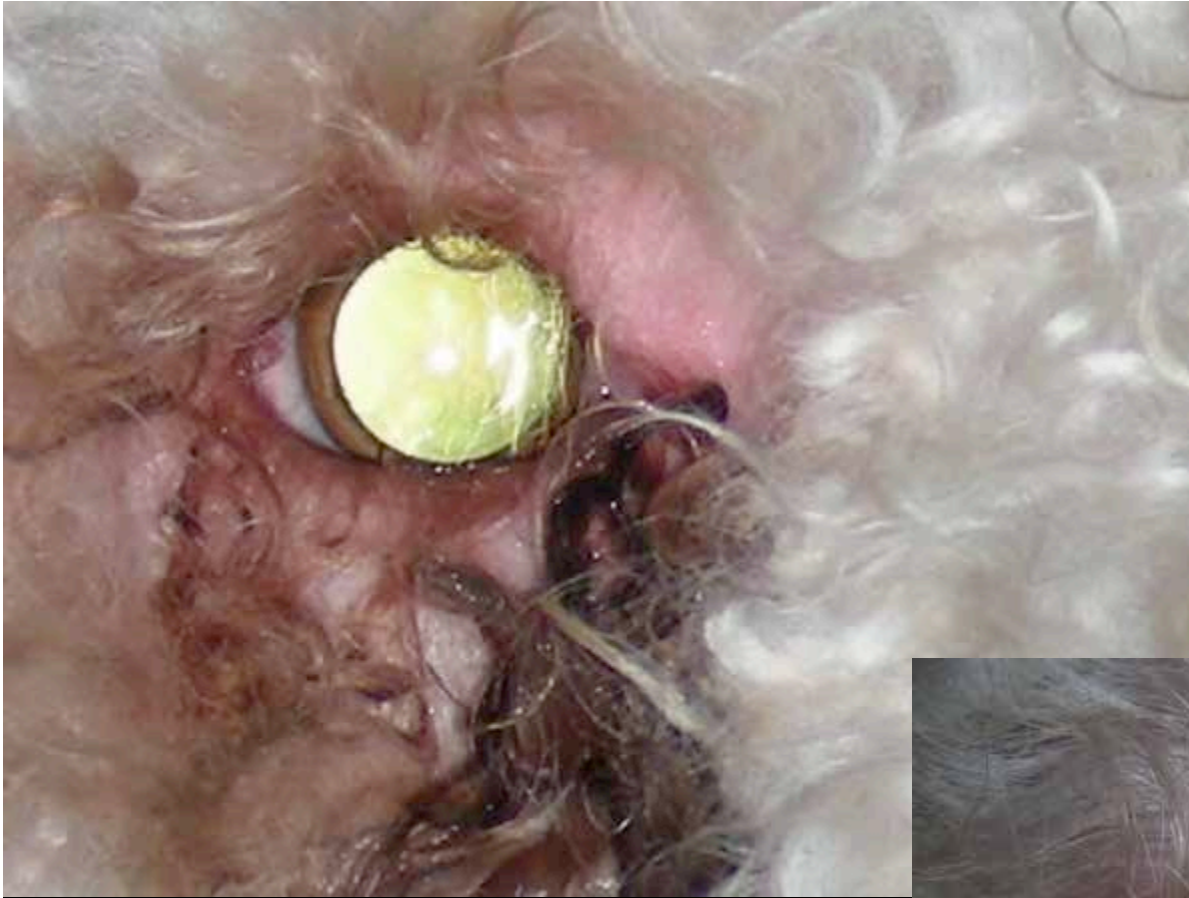

post-OP

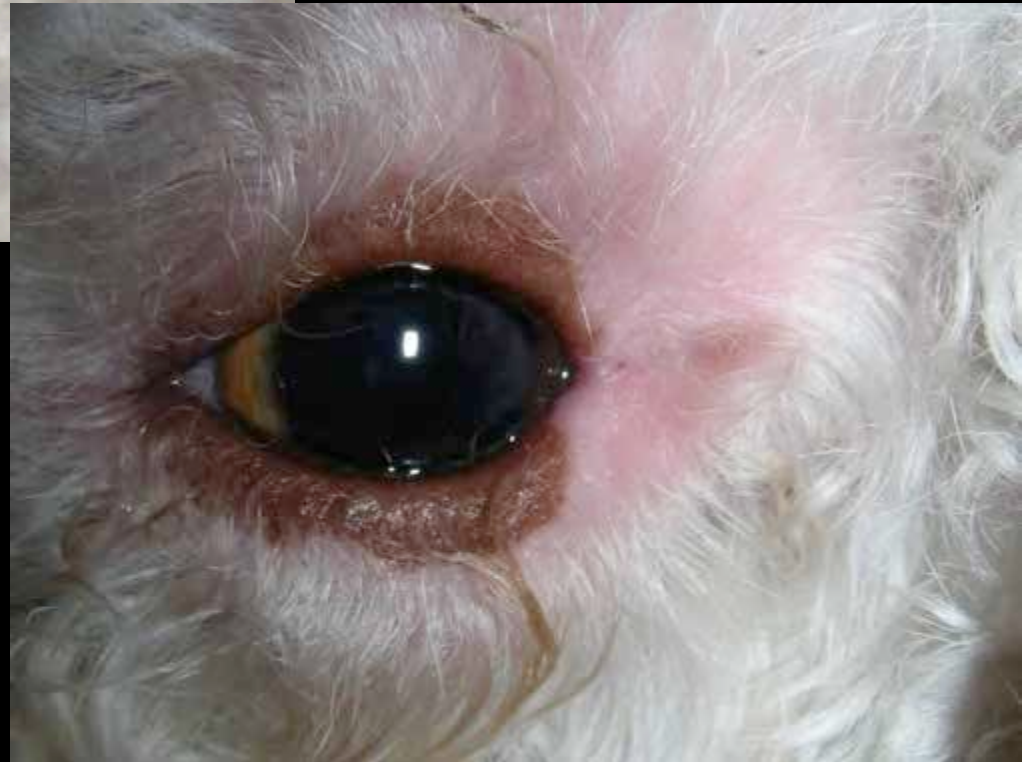



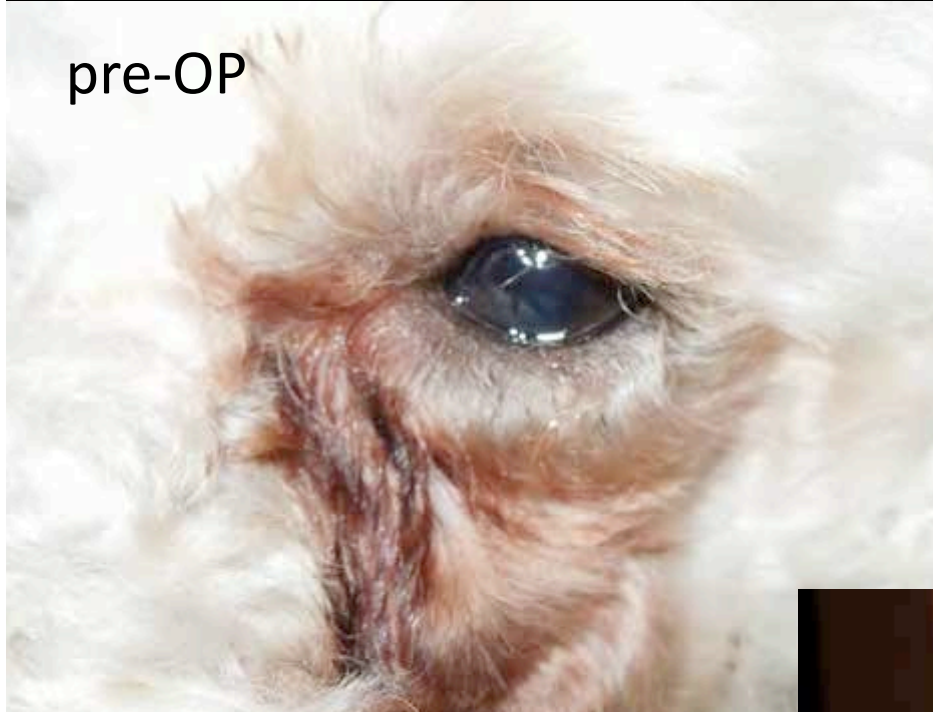pre-OP



post-OP



pre-OP



post-OP





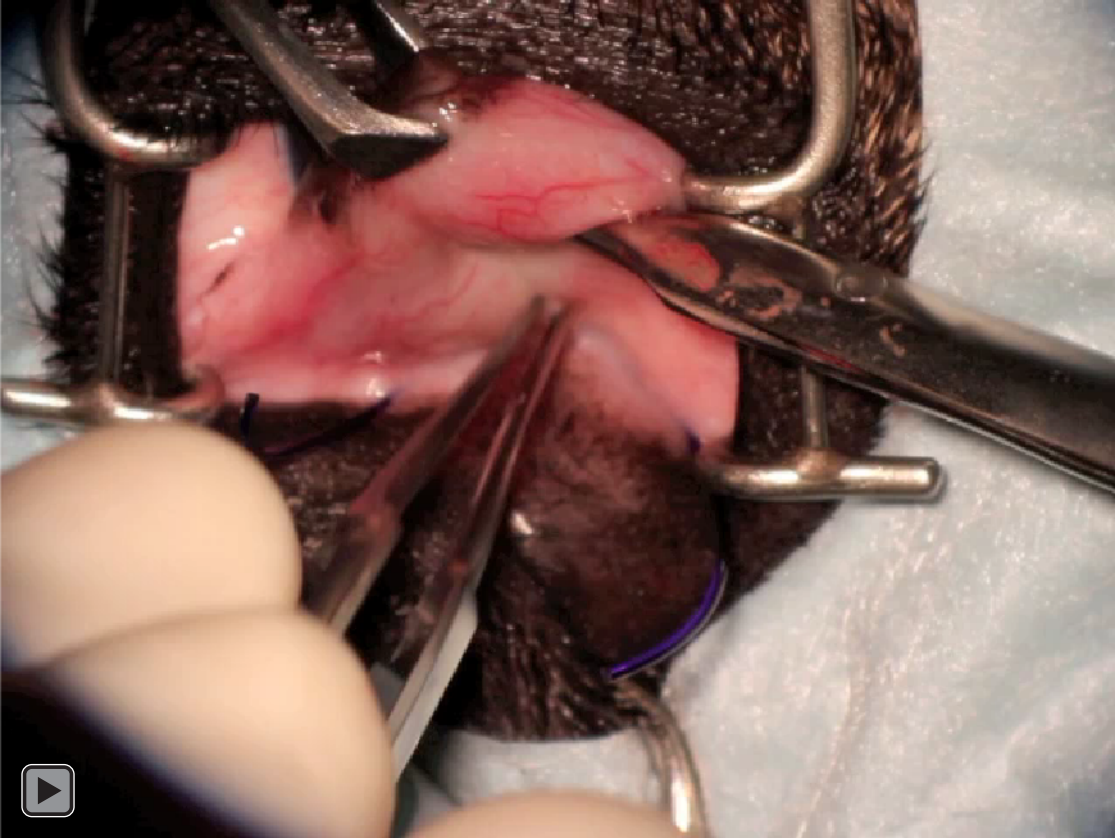# conclusion

- after a learning curve (...) the simplified nasal canthoplasty technique is quick and effective in
  - reducing palpebral fissure
  - reducing exposure keratitis
  - reducing trichiasis and epiphora
  - improving tear film
- splitting of the canaliculi allows proper tear flow even after shortening the lid length  $\gg 30\%$

# simplified nasal canthoplasty

- will result in
  - improvement if most clinical signs
  - improved patient comfort
- combined with lifelong topical therapy (ie ciclosporin, tacrolimus, +/- dexamethasone) it prevents progression of pigmentary keratitis
- the change of facial expression pleases the owners in most cases







**THANK YOU**