

## CASE REPORT

# Dacryops in a red-eared slider (*Chrysemys scripta elegans*): case report

Ingrid Allgoewer,\* Thomas Göbel,† Christian Stockhaus‡ and Ekkehard H. Schaeffer§

\*Animal Eye Practice, Spanische Allee 4, 14129 Berlin, Germany, †Department of Wildlife and Zoological Medicine, College of Veterinary Medicine, University of Florida, Gainesville, Florida, USA, ‡Small Animal Clinic, University of Leipzig, Zwickauer Str., Leipzig, Germany, §GSF-Forschungszentrum für Umwelt und Gesundheit, Neuberberg, 85758 Oberschleißheim, Germany

Address communications to:

Ingrid Allgoewer

Tel.: +49 (30) 80589868

Fax: +49 (30) 80589579

e-mail: augen@bigfoot.com

## Abstract

Clinical and histologic findings of an orbital lacrimal cyst (dacryops) in a 23-year-old female red-eared slider (*Chrysemys scripta elegans*) are described. Main ophthalmologic findings included unilateral exophthalmus, engorged episcleral vessels, periocular swelling superior to the globe, incomplete lid closure, and reduced ocular motility. Based on sonographic and cytologic examination of the tissue, the preliminary diagnosis of an orbital cyst was established. After surgical resection of the cystic structure, the eye remained visual but enophthalmic. Histopathologic diagnosis of the resected tissue was interstitial dacryoadenitis.

**Key Words:** exophthalmos, lacrimal gland, orbital cyst, reptiles

## INTRODUCTION

Congenital lacrimal cysts are reported in newborn infants as fluctuating cystic space occupying the region in the temporal upper lid, and may cause proptosis and caudal displacement of the globe.<sup>1</sup> In small animals orbital and periorbital cysts include dermoid cysts<sup>2</sup> as well as cystic structures arising from the orbital lacrimal gland, zygomatic salivary gland, mucosa of the paranasal sinuses, or from retained or buried conjunctival mucosa.<sup>3–6</sup> Acquired lacrimal cysts have been seen in the dog<sup>7–9</sup> whereas conjunctival retention cysts resulting in multiple periocular cystic structures are described in a rhinoceros viper (*Bitis nasicornis*).<sup>10</sup> This case report presents an acquired lacrimal cyst (dacryops) in a red-eared slider (*Chrysemys scripta elegans*).

## CASE REPORT

A 23-year-old female red-eared slider presented with a history of progressive swelling of the right eye. The second turtle of the owner bit her into the right periocular region several years ago. According to the owner, the bite wound was not treated and healed spontaneously. When progressive protrusion of the right eye occurred some years later the turtle was presented to a veterinarian who diagnosed a retrobulbar cyst. Aspiration was performed by the veterinarian. Some weeks after the treatment the retrobulbar swelling came back slowly. As the turtle did not seem to be disturbed

initially, the owner waited for 2 years. Upon the onset of reduced eye movements, the animal was presented for an ophthalmologic examination. It weighed 3050 g and was in good body condition. Oral examination was normal. Both eyes were visual. Direct and indirect pupillary light reflexes, dazzle and menace reflexes could be elicited. The right globe had pronounced exophthalmus and engorged episcleral vessels. The periocular swelling extended superior to the globe temporally to dorsonasally. Lid closure was incomplete and ocular motility was decreased. Retropulsion was restricted and palpation of the swelling through the upper lid revealed fluctuation. Palpation did not cause discomfort. The examination of the anterior and posterior segments was normal. No abnormalities were seen on the left side.

B-mode ultrasound (B-5500, Sonomed, Inc., Lake Success NY, USA) was performed with a 10-MHz probe under topical anesthesia (Proximetacainhydrochlorid, Proparacain POS 0.5%®, Ursapharm, Saarbruecken, Germany) and revealed a large amount of slightly echogenic fluid dorso-temporally of the globe, which seemed to be surrounded by an echodense structure (Fig. 1). Fine needle aspiration biopsy was performed with a 27-g canula. Clear, watery, red colored fluid was aspirated. The cytologic examination revealed red blood cells as well as cyst-lining macrophages and degenerated cells with amorphous eosinophilic cystic material (Fig. 2). A preliminary diagnosis of an orbital cyst was made. The tissue of origin could not be determined at this point.



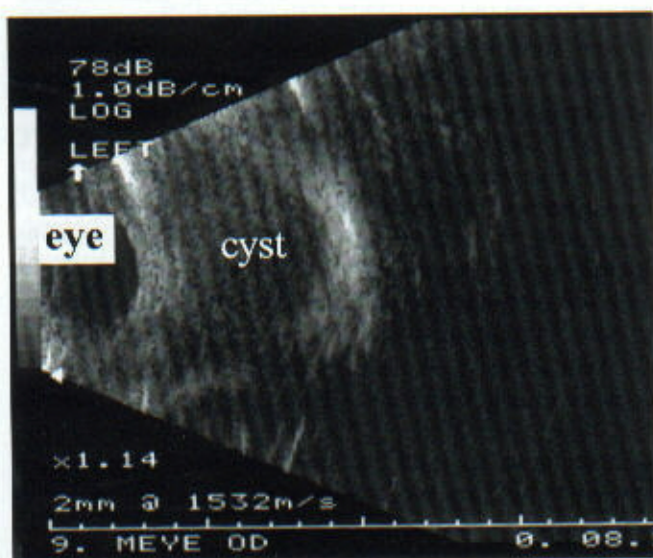


Figure 1. B-mode ultrasound image of the right orbit of the red-eared slider demonstrating the eye and the cyst.

Due to the lack of discomfort shown by the turtle, the owner was reluctant to further diagnostics and preferred to wait for another year. By that time decreased appetite and depression as well as pronounced protrusion of the affected eye was noted. The ophthalmologic examination was repeated and revealed an even more severe exophthalmus with bulging of the fluctuating mass superior to the right globe (Fig. 3a,b).

Surgical resection of the cystic structure was now requested by the client. The turtle was premedicated with ketamine 10% 50 mg/kg IM. A tracheal tube was placed and anesthesia induced with 4% isoflurane. Anesthesia was maintained with isoflurane in 100% oxygen at a flow rate of 2.5 L/min. Expiratory CO<sub>2</sub> was monitored with a capnograph. To prevent secondary bacterial infection enrofloxacin (Baytril®, Bayer Vital GmbH and Company, Leverkusen, Germany, 10 mg/kg SC) was injected.

After surgical preparation of the periocular area, a skin incision was made parallel to the right upper eye lid about 4 mm from the lid margin. After careful preparation a thin cystic wall could be identified. Dissection continued along the cyst sparing the globe and the extraocular muscles which could be well identified. Posterior to the cystic structure a fleshy firm tissue appeared which was resected along with the cyst. Upon resection hemorrhage occurred and made further identification of orbital structures difficult. As removal of the cyst caused a cavity within the orbit this space was packed with an absorbable collagen sponge (Kollagen-Haemostyptikum-Vlies®, B. Braun-Dexon GmbH, Spangenberg, Germany) to control hemorrhage. The skin wound was closed (silk, USP 6-0, Perma-Hand®, Ethicon GmbH, Norderstedt, Germany) in a simple interrupted pattern. To prevent corneal exposure a temporary tarsorrhaphy was performed (silk, USP 6-0, Perma-Hand®). The animal recovered

uneventfully. The excised tissue was submitted for histopathologic examination.

Three weeks after surgery the tarsorrhaphy sutures were removed. The skin incision had not healed and tended to dehis. Exophthalmus was still pronounced; eye movements were possible to a minimal degree only. Pupillary light reflexes were present, and the eye seemed to be visual. General performance of the turtle was good. At the next presentation 3 weeks later the globe was in a normal position and lid closure was almost normal, as were eye movements and pupillary light reflexes. There was dehiscence of the skin incision over about 3 mm. Some material, possibly residual collagen sponge, was flushed from the cavity underneath the incision.

Eight months later the turtle was in good body condition. The right eye seemed to be slightly enophthalmic. Although the upper lid movements were restricted, lid closure was complete. Ocular motility was normal, and the eye remained visual. The right superior orbital rim seemed to be enlarged when compared to the left side (Fig. 4a,b).

#### HISTOPATHOLOGIC FINDINGS

The surgically removed orbital cystic tissue was fixed in neutral buffered formalin and thereafter imbedded in paraffin wax. The 3–4-µm thin sections were stained with H&E. A periodic-acid Schiff (PAS) reaction was also performed.

Histologically the excised tissue consisted of tubulo-alveolar sero-mucoid glandular tissue and ducts. Many ducts were dilated. Due to increased pressure the lacrimal epithelium was atrophied and there was intensified mucus production (Fig. 5a). Disseminated round cell infiltration was present within the interstitial spaces and the lacrimal epithelium was free of mitoses (Fig. 5b). No porphyrin crystals were identified in any section. The diagnosis was interstitial dacryoadenitis.

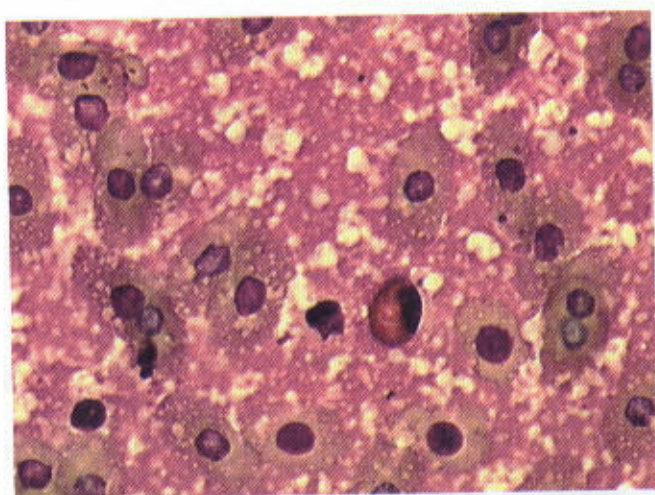
#### DISCUSSION

Differential diagnoses of periocular swellings in reptiles include hypovitaminosis A<sup>11–14</sup> infectious diseases,<sup>12,15</sup> abscessation,<sup>11,12,14,16</sup> myiasis,<sup>17</sup> cystic<sup>10</sup> and vascular diseases,<sup>18</sup> trauma, and neoplasia.<sup>19</sup> Clinical examination of the red-eared slider revealed a fluctuating mass within the right upper lid. Sonography demonstrated a fluid-filled cystic structure temporodorsally to the eye. Abscessation and neoplasia were ruled out by fine needle aspiration biopsy. The tentative diagnosis of an orbital cyst was confirmed during surgery. Chelonians possess a lacrimal gland and a Harderian

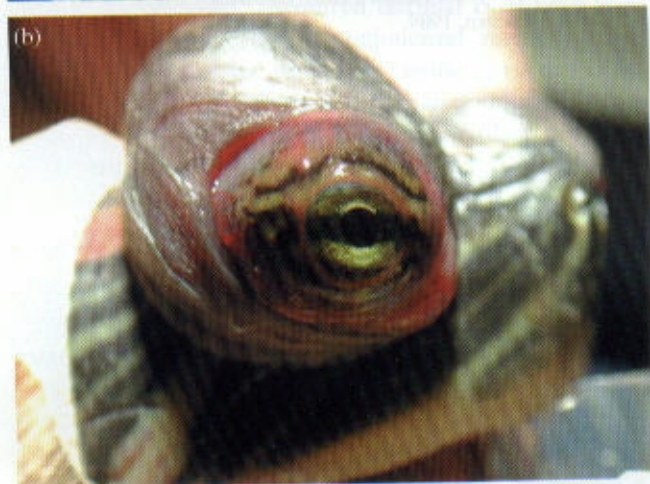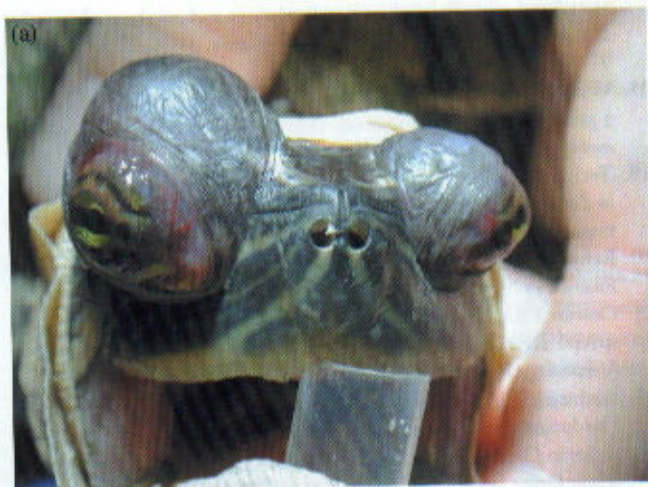

Figure 4. (a) and (b) Eight months after resection of the dacryops of the right orbit of the red-eared slider: the right eye is enophthalmic and the dorsal orbital rim is enlarged.

Figure 5. (a) Lacrimal gland showing mucus production. PAS, scale bar 25 µm. (b) Lacrimal gland showing dilatation of lacrimal ducts with atrophy of lacrimal epithelium due to increased pressure caused by disseminated round cell infiltration. PAS, scale bar 64 µm.

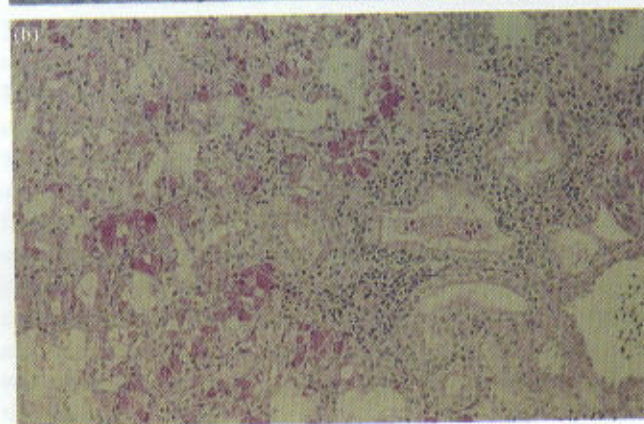
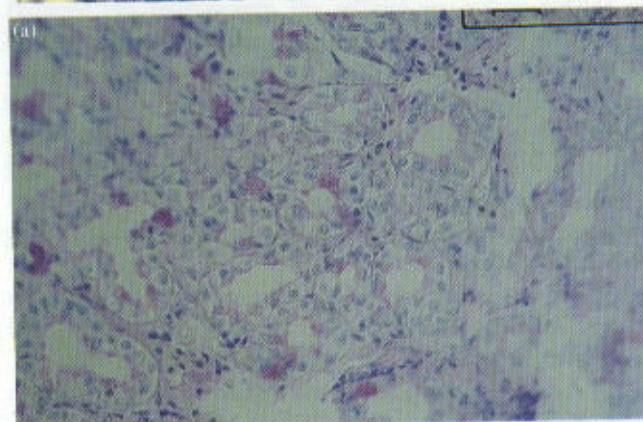




**Figure 2.** Fine needle aspiration biopsy of the cystic material of the right orbit of the red-eared slider. Note the erythrocytes, cyst lining macrophages and degenerated cells with amorphous eosinophilic cystic material. May-Gruenwald-Giemsa,  $\times 1000$ .



**Figure 3.** (a) and (b) Exophthalmos of the right eye of the red-eared slider with pronounced swelling of the region temporodorsally of the eye. The animal is intubated.





gland;<sup>12,20,21</sup> both could have contributed to the cyst as well as buried conjunctiva.<sup>10</sup> The anatomical position of the cyst in our case suggests that we are dealing with the lacrimal gland rather than the Harderian gland. The latter is located inferior and anterior to the globe within the orbit.<sup>21</sup> Abnormalities of the Harderian gland may cause exophthalmos.<sup>22,23</sup> Upon histopathologic examination the cystic tissue was determined to derive from the lacrimal gland. The PAS stain revealed seromucoid secretion in the ducts which is reported for the lacrimal gland as opposed to the serous Harderian gland function.<sup>21</sup> Also, we could not identify porphyrin crystals in any section: these are described as characteristic contents of the Harderian gland in rodents.<sup>22,23</sup> The histologic diagnosis of interstitial dacryoadenitis was made. The chronic interstitial inflammatory reaction of the lacrimal gland may be interpreted as an immunocytic reaction, a late complication of the bite wound which had been reported by the owner.

## REFERENCES

1. Duke-Elder S. Normal and abnormal development. In: *System of Ophthalmology*, Vol. III, Part 2. (ed. Duke-Elder S) CV Mosby, St Louis, 1963; 911-923.
2. Walde I, Hittmair K, Henninger W, Czedik-Eisenberg T. Retrobulbar dermoid cyst in a Dachshound. *Veterinary and Comparative Ophthalmology* 1997; 7 (4): 239-244.
3. Martin CL, Kaswan RL, Doran CD. Cystic lesions of the peri-orbital region. *Compendium of Continuing Education for Veterinary Practitioners* 1987; 9: 1022-1028.
4. Ramsey DT, Fox DB. Surgery of the orbit. *Veterinary Clinics of North America, Small Animal Practice* 1997; 27 (5): 1215-1264.
5. McCalla TL, Moore CP. Exophthalmus in dogs and cats: Part 2. *Compendium of Continuing Education for Veterinary Practitioners* 1989; 11 (8): 911-923.
6. Gerding PA. Epiphora associated with canaliculops in a dog. *Journal of the American Animal Hospital Association* 1991; 27: 424-426.
7. Playter RF, Adams LG. Lacrimal cyst (dacryops) in two dogs. *Journal of the American Animal Hospital Association* 1977; 17: 736-737.
8. Murphy CJ, Bellhorn RW, Buyukmihci NC. Bilateral conjunctival masses in two dogs. *Journal of the American Veterinary Medical Association* 1989; 195 (29): 225-228.
9. Harvey CE, Koch SE, Rubin LF. Orbital cyst with conjunctival fistula in a dog. *Journal of the American Veterinary Medical Association* 1968; 153 (11): 1432-1435.
10. Cooper JE. Exophthalmia in a rhinoceros viper (*Bitis naicornis*). *Veterinary Record* 1975; 97: 130-131.
11. Davidson MGD. Ophthalmology of exotic pets. *Compendium of Continuing Education for Practising Veterinarians* 1985; 7 (9): 724-737.
12. Millichamp NJ, Jacobson ER. Diseases of the eye and ocular adnexae in reptiles. *Journal of the American Veterinary Medical Association* 1983; 11: 1205-1212.
13. Elkan E, Zwart P. The ocular disease of young terrapins caused by vitamin A deficiency. *Veterinary Pathology* 1967; 4: 201-222.
14. Holt PE, Cooper JE, Needham JR. Diseases of tortoises: a review of seventy cases. *Journal of Small Animal Practice* 1979; 20: 269-286.
15. Leonard JL, Shields RP. Acid-fast granuloma in a turtle's eye. *Journal of the American Veterinary Medical Association* 1970; 157: 612-613.
16. Schumacher J, Pellicane CP, Heard DJ, Voges A. Periorbital abscess in a three-horned Chameleon (*Chamaeleo jacksonii*). *Veterinary and Comparative Ophthalmology* 1996; 6: 30-33.
17. Thomas CL, Artwohl JE, Pearl RK, Gardiner CH. Swollen eyelid associated with *Foleyella* sp. infection in a chameleon. *Journal of the American Veterinary Medical Association* 1996; 209 (5): 972-973.
18. Whittaker CLG, Schumacher J, Bennett RA et al. Orbital varix in a green iguana (*Iguana iguana*). *Veterinary and Comparative Ophthalmology* 1997; 7 (2): 101-104.
19. Tucker MJ. Tumors of the Harderian gland. In: *Pathology of Tumors in Laboratory Animals*. (ed. Turusov VS) IARC Scientific Publications, Lyon, 1979; 135-138.
20. Rehorek SJ. Squamate Harderian gland: An overview. *Anatomical Record* 1997; 248: 301-306.
21. Cowan FBM. The homology of cranial glands in turtles: with special reference to the nomenclature of 'salt glands'. *Journal of Morphology* 1973; 141: 157-170.
22. Rothwell TLW, Everitt AV. Exophthalmus in aging rats with Harderian gland disease. *Laboratory Animals* 1986; 20: 97-100.
23. Kehrein G. Histologische Klassifikation der Tumoren der Harderschen Drüse bei der NMRI-, CBA- und Balb/c-Maus. Dissertation, LMU, München, 1989.