

## ORIGINAL REPORT

# A transconjunctival surgical technique for dacryocystotomy in dogs with foreign body-induced dacryocystitis

Ingrid Allgoewer<sup>1</sup> | Petr Soukup<sup>1</sup> | Eberhard Ludewig<sup>2</sup>

<sup>1</sup>Animal Eye Practice, Berlin, Germany

<sup>2</sup>Clinical Unit of Diagnostic Imaging, Department for Companion Animals and Horses, University of Veterinary Medicine Vienna, Vienna, Austria

## Correspondence

Ingrid Allgoewer, Animal Eye Practice, Lindenthaler Allee 9, 14163 Berlin, Germany.

Email: [ia@tieraugen.com](mailto:ia@tieraugen.com)

## Abstract

**Purpose:** The purpose of this study is to describe a simplified, less invasive dacryocystotomy technique that allows for complete inspection of the canine lacrimal sac and to retrospectively evaluate this surgical technique in a larger series of dogs. The anatomical background of the canine nasolacrimal system is described as a basis for the surgical technique.

**Methods:** Records of dogs from 2003 to 2023 which were diagnosed with dacryocystitis due to presumed foreign body and underwent surgical exploration and removal of foreign bodies within the lacrimal sac using this technique were reviewed. Postoperative treatment and outcome were evaluated.

**Results:** Records of 48 dogs were included. A foreign body was discovered during the surgery or upon retrieval of the catheter in 85% of cases (41/48). An indwelling catheter was placed in 83% of cases (40/48) for a median of 21 days. At the last recheck, the nasolacrimal duct was patent in 87% of the cases (41/47). The median follow-up time was 34 days (3–1255 days). The most commonly affected breeds were Golden retrievers (11) and dachshunds (8). The following complications occurred: two dogs removed or partly removed the catheter themselves (day 7, day 14), and one dog showed marked irritation at the catheter site which had to be removed by day 10.

**Conclusions:** The transconjunctival dacryocystotomy technique is simple and less invasive than other described techniques with a successful long-term outcome in the majority of cases.

## KEYWORDS

anatomy, grass awn, lacrimal sac, nasolacrimal duct, stenosis, surgery

## 1 | INTRODUCTION

Foreign bodies lodged within the canine lacrimal sac cause mucopurulent ocular discharge resistant to topical therapy and repeated flushing of the nasolacrimal duct. Reports on surgical techniques for the removal of foreign bodies from the lacrimal sac are sparse.<sup>1–4</sup> Most

techniques described in the literature involve a transpalpebral transosseous approach.<sup>1–4</sup> One case series describes the splitting of the lacrimal canaliculus as an approach to the lacrimal sac.<sup>5</sup> A non-invasive technique is described in a small case series with an ultrasonography-guided extraction of plant-based foreign bodies in the lacrimal sac with alligator forceps.<sup>6</sup>

The purpose of this study is to describe a minimal invasive dacryocystotomy technique that allows for complete inspection of the canine lacrimal sac and to retrospectively evaluate this surgical technique in a larger series of dogs. The anatomical background of the canine nasolacrimal system is described as an introduction to the surgical technique.

## 1.1 | Anatomy of the canine nasolacrimal drainage system

The nasolacrimal drainage system serves as a conduit for tear flow and consists of the upper and lower lacrimal puncta (punctum lacrimale superio et inferio), the lacrimal canaliculi (canaliculi lacrimalia), the lacrimal sac (saccus lacrimalis) and the nasolacrimal duct (ductus nasolacrimalis). The nasolacrimal duct starts at the lacrimal punctum and continues into the nasal cavity.<sup>7</sup>

The following landmark bony structures around the nasolacrimal duct are described (Figure 1): In carnivores, the lacrimal bone forms a process (Figures 1 and 2, processus frontalis<sup>8</sup> and as described in cats, the upper lacrimal canaliculus runs caudolaterally to this inconspicuous structure.<sup>9</sup> The lacrimal bone shows a depression on its orbital side (Figures 1 and 2, fossa sacci lacrimalis), where the lacrimal sac is situated.<sup>7,10</sup> The lacrimal foramen (Figure 3), also formed by the lacrimal bone, serves as the bony opening for the nasolacrimal duct and is the connection from the lacrimal fossa to the nasolacrimal canal.<sup>7,10</sup> This canal surrounds one third of the nasolacrimal duct and consists of the lacrimal and the maxillary bones.<sup>7,10,11</sup> The middle part of the nasolacrimal duct is

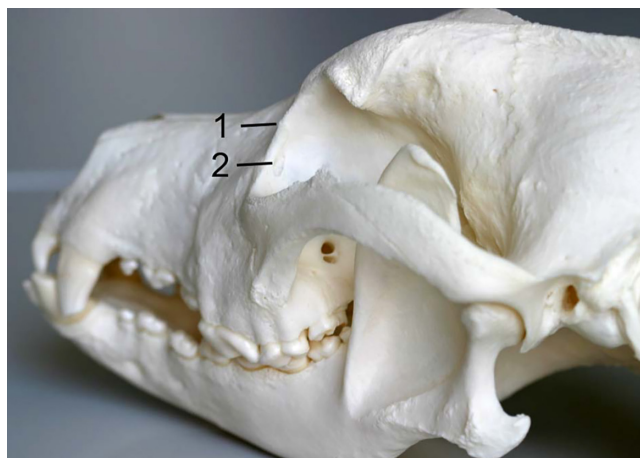


FIGURE 1 Skull of a German shepherd dog where the inconspicuous frontal process of the lacrimal bone (1) and the lacrimal fossa (2) are visible.

situated ventral to the basal lamina of the ventral nasal bone. There are no bony structures adjacent to the distal part.<sup>10,11</sup> Please note that the description refers to mesocephalic dogs. However, the anatomy of brachycephalic skulls varies exceedingly.<sup>12–14</sup>

For a better three-dimensional understanding and differentiation of a number of diseases of the nasolacrimal system, the use of imaging techniques is helpful, especially -computed tomographic dacryocystography.<sup>9,13–15</sup>

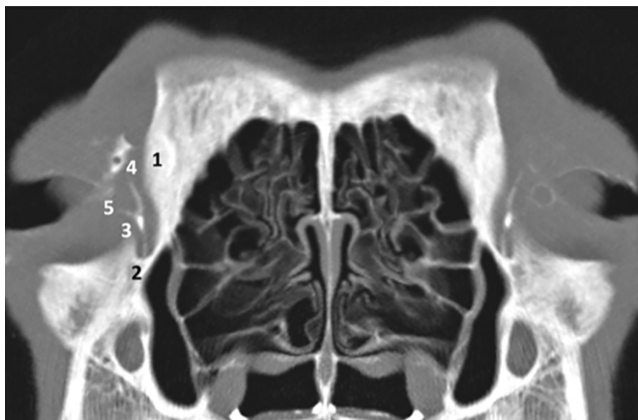
Paying surgical attention to the lacrimal canaliculi and the lacrimal sac, the following anatomical facts are helpful: As noted in Figures 2 and 3, the lacrimal canaliculi and especially the lacrimal sac are not completely surrounded by the lacrimal bone. Therefore, it is easily accessible for surgery. The canaliculi are 3–7 mm long and 0.5–1 mm in diameter.<sup>10,11,16</sup> Both canaliculi join the poorly developed lacrimal sac<sup>11,16</sup> with a length of 1–5 mm and a diameter of 0.5–2 mm.<sup>10,16</sup> The lacrimal foramen is the narrow-most section of the nasolacrimal sac (Figure 3).<sup>15</sup>

## 1.2 | Surgical procedure

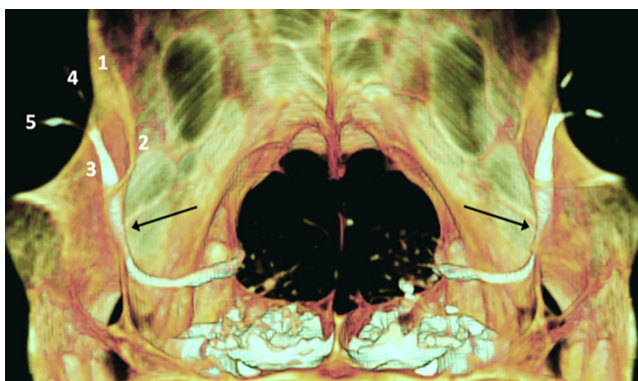The surgery is performed under general anesthesia. The dog is placed in lateral recumbency with the head positioned on a vacuum cushion tilting the nose upwards and pointing toward the end of the table. As magnification (5–7×) is necessary, the use of a surgical microscope is recommended (Video 1, S1).

The lids are held open with a lid speculum, the authors' preference is a Williams eyelid speculum. The nictitans is pulled up as far as possible with a nictitans forceps (e.g., Graefe) and kept in that position with a tissue clamp (Backhaus). The surgical site was prepped with a 2% povidone-iodine ocular solution. Wilder lacrimal probes are inserted into both lacrimal canaliculi to facilitate orientation for surgical dissection (Figure 4A). In most cases, the tips of the Wilder probes touch each other within the lacrimal sac which can be felt by the surgeon. Slight shifting and moving of the probe tips up and down allow for exact orientation (Video 1, S1).

A sharp scalpel incision of 7–10 mm is made through the conjunctiva at the base of the nictitans in the direction of the tips of the Wilder probes (Figure 4B,C). Blunt dissection down to the lacrimal sac is performed with Stevens tenotomy scissors. The direction is toward the touching point of the two lacrimal probes within the lacrimal sac (Figure 4D). The lacrimal sac is opened by a stab incision with the scalpel blade No. 15 (Figure 5A). Typically, a foreign body is stuck within the lacrimal sac at the bottleneck position where the nasolacrimal duct enters the lacrimal bone through the lacrimal foramen



**FIGURE 2** Transverse CT image (CT-Dacryocystography) of a normal mesocephalic dog at the level of the lacrimal fossa (bone window). The frontal process (1) and the lacrimal fossa (2) are easily seen. The lacrimal drainage system is filled with contrast medium (1:2 mixture of Omnipaque® 300 and methyl cellulose Adatocel®) and the upper (4) and lower (5) canaliculi, with its union in the lacrimal sac (3), are visible.



**FIGURE 3** Three-dimensional reconstruction of the CT-Dacryocystography in a normal mesocephalic dog. The neurocranial bones are cut off. The lacrimal sac (3) is easily accessible for surgery. The arrows point toward the lacrimal foramen. At this point, the foreign bodies are typically stuck as this is the narrow-most part of the lacrimal sac where the nasolacrimal canal enters the lacrimal bone. Morphologically, the lacrimal sac is more a dilatation of the duct. Frontal process of the lacrimal bone (1), lacrimal fossa (2), upper/lower lacrimal canaliculi (4, 5).

(Figure 5D, Video 1, S1). After extraction of the foreign body with a hemostat (Figure 6), an injection of viscoelastic can be used to float up any remaining debris into the wound where it can be removed (Video 1). Afterward, an indwelling tomcat urinary catheter with a closed end and side holes (Buster Jackson type cat catheter with stylet 1.00 × 130MM, Henry Schein, Gallin, Germany) is fed through the superior lacrimal punctum into the nasal cavity. The superior punctum is used for anatomical reasons and ease of insertion of the catheter. The stylet is

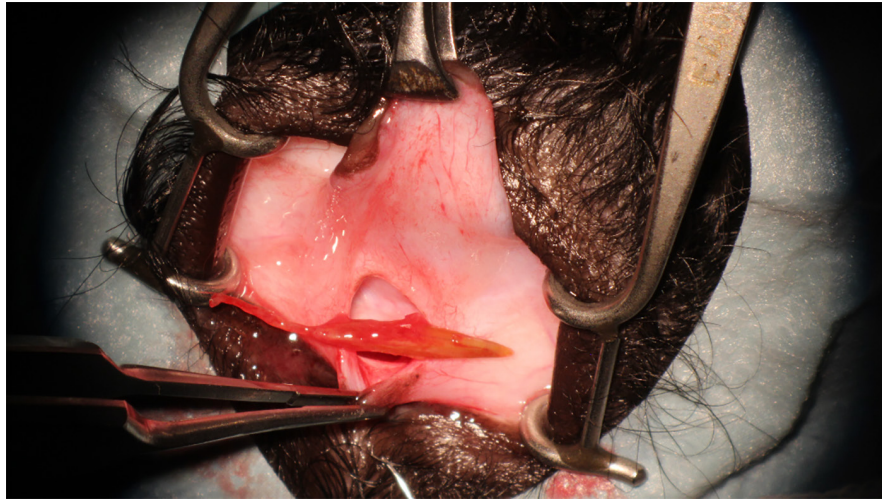
removed and the Luer lock adapter is cut off. The catheter is folded over and sutured to the skin close to the nasal canthus (Vicryl® 6-0, Ethicon, Johnson&Johnson Surgical Technologies, Neuss, Germany) (Figure 7B). The catheter's end does not exit the nostril but remains within the nasal cavity, thereby avoiding constant irritation of the nostril (Figure 7A). The conjunctival incision is closed with a single continuous absorbable suture and buried knots (Vicryl® 6-0, Ethicon, Johnson&Johnson Surgical Technologies).

The surgery is performed as an ambulatory procedure under general anesthesia. Carprofen (4 mg/kg, Rimadyl®; Zoetis, Berlin, Germany) is given intravenously and amoxicillin-clavulanic acid (Synulox®, Zoetis, Germany) subcutaneously at the time of induction. After the surgery, an Elizabethan collar is used until the catheter is removed. A combination of antibiotics and steroidal anti-inflammatory eye drops (dexamethasone, neomycin sulfate, polymyxin-B sulfate; Ioptomax®, Alcon, Germany) is applied topically two to three times daily over 3 weeks. Carprofen (Rimadyl®, Zoetis) and a broad-spectrum antibiotic (amoxicillin clavulanic acid, Synulox®, Zoetis) are administered orally over 5 days. Ideally, the indwelling catheter remains in place for 3 weeks. Removal of the catheter is performed under topical anesthesia.

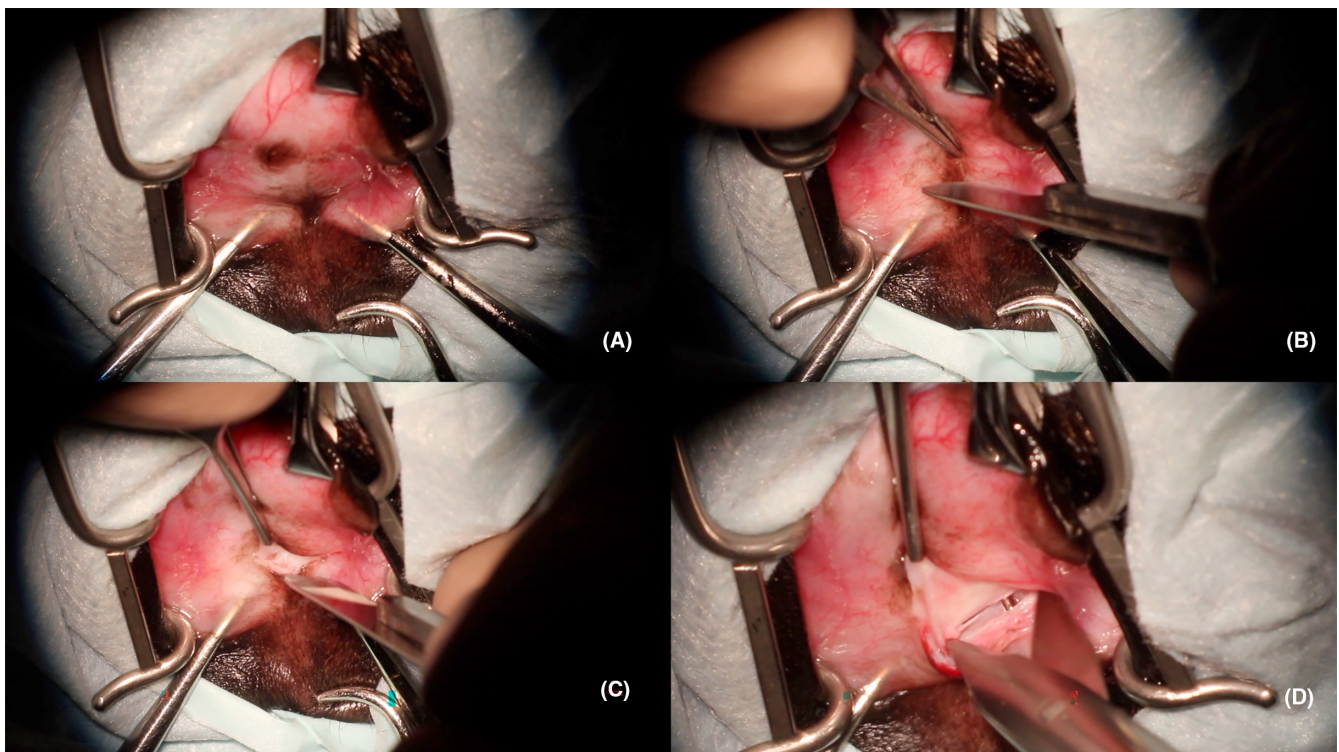
## 2 | MATERIALS AND METHODS

A retrospective evaluation (2003–2023) of cases that underwent the surgical procedure described above was performed. Exclusion criteria were absence of typical clinical signs (i.e., mucopurulent to purulent ocular discharge, obstructed nasolacrimal duct; Figure 8) and the presence of cystic structures within the nasolacrimal duct. All dogs underwent a complete ophthalmic examination including a slit lamp biomicroscopy and indirect ophthalmoscopy examination, Schirmer tear test I (Tear Touch Blu®, Madhu Instruments Pvt. Ltd., New Delhi, India), fluorescein staining (Fluoro-Touch®, Madhu Instruments Pvt. Ltd.). In some cases, bacterial culture was performed by gently evacuating fresh discharge from canaliculi, and if performed, these results were evaluated. Flushing of the nasolacrimal canal from the superior lacrimal punctum under topical anesthesia (proxymetacaine hydrochloride; Proparacain-POS 0.5%®, Ursapharm, Germany) was attempted in all cases.

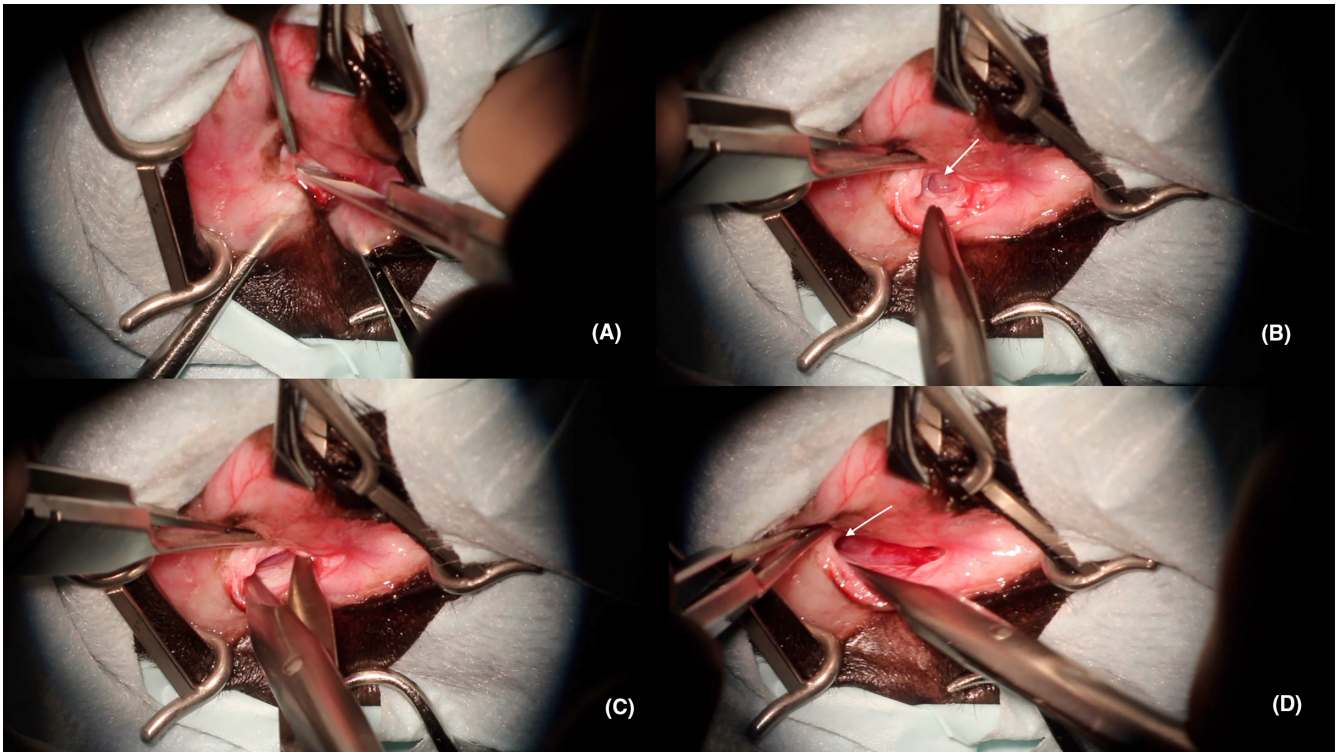
Case signalment (breed, age, sex, age at the time of surgery), duration of clinical signs prior to surgery, post-surgical therapy, bacterial culture results, identification of foreign body, length of the follow-up as well as the time until removal of the catheter and patency of the nasolacrimal duct at the last recheck were noted. GERVO guidelines



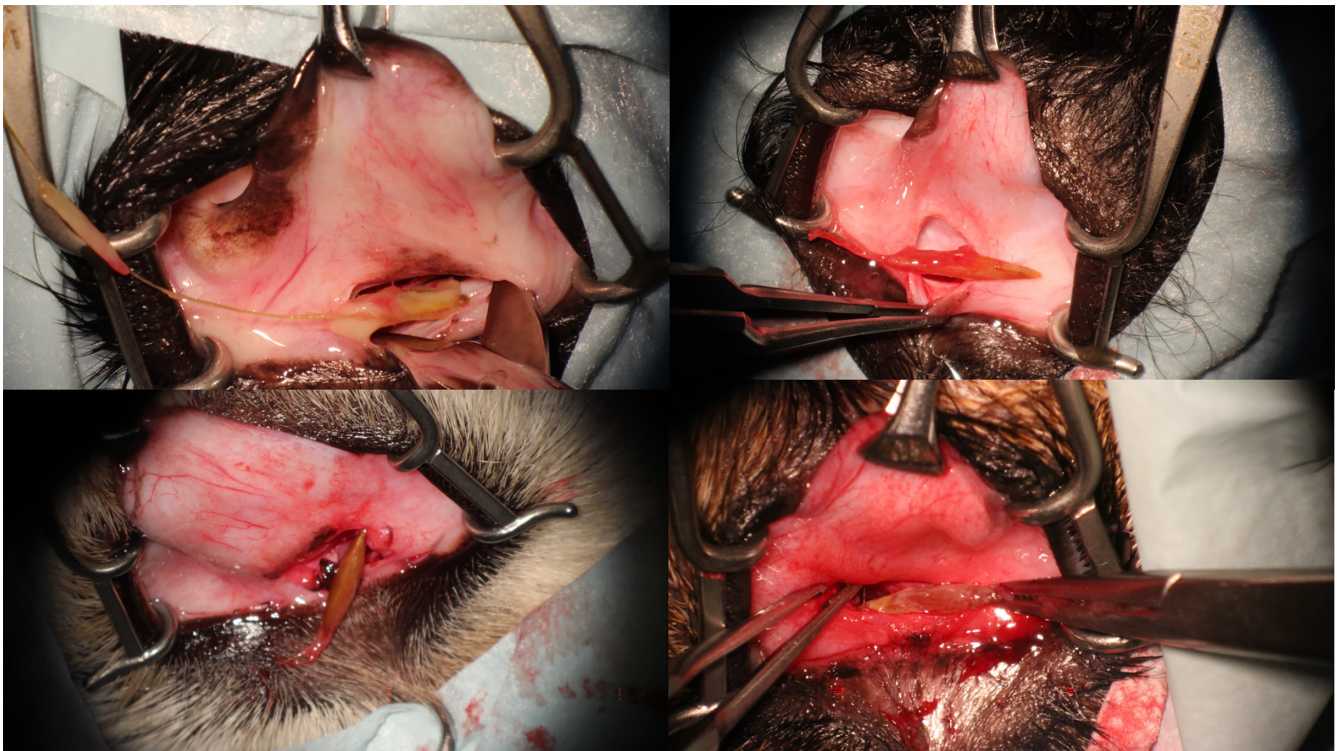
**VIDEO 1** Transconjunctival dacryocystotomy. The dog is positioned in lateral recumbency with the head slightly tilted and the nose pointing towards the surgeon at the end of the table. The surgery is performed under the microscope with a magnification of about 5x. The lid speculum is spread and the nictitans is pulled up maximally with a Graefe's forceps. Wilder tear probes are inserted into the lacrimal canaliculi for orientation. The initial cut is performed with a scalpel blade oriented towards the tips of the probes followed by blunt dissection with Stevens tenotomy scissors. A stab incision opens the lacrimal sac. Blunt dissection extends the incision longitudinally until the entire length of the lacrimal sac can be inspected. Attention is focused on the narrow distal part of the lacrimal sac where the nasolacrimal duct enters the bony part. Most foreign bodies are located there. A cylindrical sponge is used to wipe the lacrimal sac. In the video, the foreign body is obvious. It is carefully grasped and pulled out with a hemostat. Viscoelastic is injected into the lacrimal sac in order to float debris out of the lacrimal sac. A tomcat catheter is inserted in the superior lacrimal punctum and fed forward through the lacrimal sac into the nasolacrimal duct. The conjunctival wound is closed with a continuous inverted suture with buried knots (absorbable suture material 6-0).



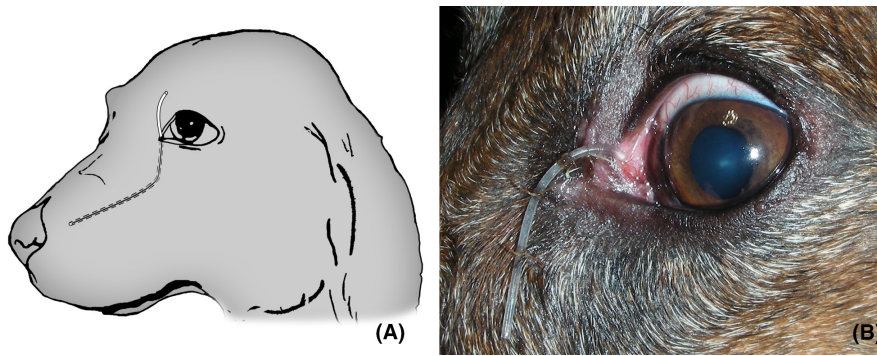
**FIGURE 4** Transconjunctival dacryocystotomy step-by-step: (A) Positioning: the lid speculum is spread and the nictitans is maximally pulled up. Wilder tear probes are inserted in the lacrimal canaliculi for orientation. (B, C) Initial cut with the scalpel blade oriented toward the tips of the probes. (D) Blunt dissection with the Stevens tenotomy scissors.



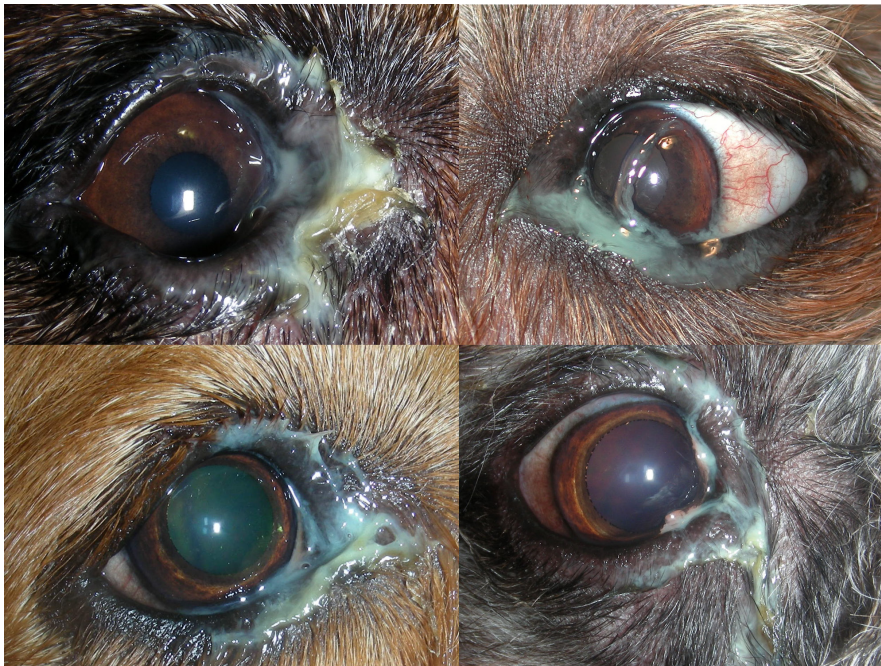**FIGURE 5** Transconjunctival dacryocystotomy step-by-step (continued): (A) Stab incision with scalpel blade to enter the lacrimal sac. (B) Lacrimal sac is exposed, arrow points to lacrimal sac. (C) Further blunt dissection opens the lacrimal sac longitudinally. (D) The lacrimal sac is exposed over the entire length exposing the entrance of the lacrimal duct into the lacrimal bone. The arrow points toward the lacrimal foramen. This is the location where most foreign bodies are stuck.



**FIGURE 6** Grass awns extracted from the lacrimal sac.



**FIGURE 7** (A) Sketch showing the position of the catheter within the nasolacrimal duct. Inserted in the upper lacrimal punctum, the distal end of the catheter does not exit the nostril to avoid irritation. (B) The catheter remains in place for about 3 weeks.



**FIGURE 8** Selection of dogs with foreign body-induced dacryocystitis. The clinical presentation is quite uniform. Moderate to severe mucopurulent discharge in the absence of irritative symptoms is characteristic. Blepharospasm, corneal, and intraocular inflammatory signs are typically lacking.

on studies using archived tissues, images, samples, or medical records were followed and the retrospective study was approved by the responsible authority (Landesamt für Gesundheit und Soziales, Berlin, Germany) under the registration number StN° 033–23.

### 3 | RESULTS

In total, 48 dogs that underwent surgery for suspected lacrimal sac foreign body were included in the study (2003–2023). The most common breeds included Golden Retriever (11), Dachshund (8), Labrador Retriever (2), Parson Russell Terrier (2), Shih Tzu (2), Havanese (2), Boxer (2), poodle (2) and mixed-bred dogs (9) (see [Table S1](#)). Ten dogs were intact females, 14 spayed females, 18 intact males, and 6 castrated males. Median age of presentation was 4.17 years (0.5–13.2 years).

All dogs were presented for unilateral mucopurulent to purulent ocular discharge of variable duration ([Figure 8](#)).

According to the owner, clinical signs were present for a median of 43 days (2–1460 days). The dogs were treated with topical antibiotics and/or steroidal anti-inflammatory medication prior to presentation with no improvement.

Upon ophthalmic examination, the dogs showed no blepharospasm with unilateral mucous, mucopurulent, or purulent discharge, and conjunctival hyperemia. The Schirmer tear test I was above 20 mm/min in all dogs but one which showed mild clinical signs of bilateral keratoconjunctivitis sicca. No related corneal changes were observed and the fluorescein test was negative in all dogs. The passage of saline solution flushed into the superior lacrimal punctum was blocked toward the nostril but abundant purulent secretion, usually with tinges of blood exited at the inferior lacrimal punctum. The flushing procedure seemed to be painful in many of these dogs as they typically showed defense reactions during that procedure. The presumptive diagnosis of “dacryocystitis with possible foreign body” was established. The indication for surgery was based solely on the clinical findings, as diagnostic

imaging techniques were not pursued. Aerobic bacterial culture was performed in 44% of the cases (21/48). Negative culture results were present in 43% of samples (9/21). Altogether 13 bacterial isolates were obtained, and the most common isolates were *Staphylococcus pseudintermedius* (3), *Pseudomonas aeruginosa* (3), and *Pantoea agglomerans* (2).

All dogs underwent dacryocystotomy via the transconjunctival approach. A grass awn or parts of an awn were delivered from the lacrimal sac during the surgery in 85% (41/48) of the dogs. In one case, a foreign body was not identified during surgery; however, upon removal of the catheter after 33 days, the awn was attached to the catheter. In that case, the foreign body had already passed the lacrimal foramen and was located in the more distal part of the nasolacrimal duct. In all the other cases the foreign bodies were stuck just proximal to the lacrimal foramen (40/48). The foreign bodies could easily be extracted with a hemostat (Figure 6). In 19% of cases (9/48), there was granulation or necrotic tissue in the lacrimal sac and around the foreign body. In those cases, a gentle curettage with a bone curette was performed. A tomcat catheter was successfully placed in 83% of cases (40/48) and was sutured in place for a median of 21 days (7–46 days). In eight cases, the placement of a catheter was not possible. Postoperative recovery was uneventful. The ocular discharge decreased over time. The median follow-up time was 34 days (3–1255 days). At the last recheck, the nasolacrimal duct was patent in 87% of the cases (41/47, one dog was lost to follow-up after 8 days and not included in final numbers), this was assessed via flushing the duct. Six cases did not regain patency (out of those, five did not have a catheter placed). Nevertheless, the clinical signs of dacryocystitis resolved completely in all the cases with long-term follow-up. The following complications occurred: two dogs removed or partly removed the catheter themselves (day 7 and day 14), and one dog showed marked irritation at the catheter site which had to be removed by day 10. For further details of the individual cases see Table S1.

## 4 | DISCUSSION

Plant foreign bodies in the canine lacrimal sac cause copious mucopurulent or purulent ocular discharge and a blockage of the nasolacrimal duct that does not resolve after topical or systemic antibiotic and/or anti-inflammatory therapy. Typically, the dogs are treated for several weeks to months before presentation. The clinical examination shows a non-painful eye and no corneal involvement. A total or subtotal blockage of the nasolacrimal duct is revealed by flushing from the superior punctum which is

painful and causes purulent to sanguineous discharge from the lower punctum. Imaging techniques such as ultrasound, radiography-based dacryocystorhinography, and computed tomographic dacryocystography are useful tools to demonstrate nasolacrimal obstruction.<sup>6,16–18</sup> Due to their small size and attenuation characteristics, plant foreign bodies are not reliably detectable using computed tomography. To our knowledge, the frequency of detection of grass awns in the lacrimal sac or the nasolacrimal duct by the use of computed tomography is not reported. However, low detection rates of grass awns in other parts of the body have been documented.<sup>19–21</sup> Because of the striking clinical presentation of foreign body-induced dacryocystitis and the low detection rates of grass awns, surgery was performed without diagnostic imaging in our cases.

The dacryocystotomy techniques described in the literature involve a rather invasive transpalpebral transosseous approach.<sup>1,4</sup> Another approach results in a permanent opening of one of the canaliculi<sup>5</sup> and the whole lacrimal sac which could lead to permanent scarring and reduced function. Taking the anatomy of the lacrimal sac into account, a transconjunctival approach was developed. This technique is simple and quick to perform causing minimal trauma to the affected structures. Furthermore, only basic fine instruments are needed as bone is not penetrated. As the lacrimal sac is located superficially within the orbit, it is readily accessible through the conjunctiva. The foreign body is typically located just proximal to the lacrimal foramen. It acts as a bottleneck from the rather wide lacrimal sac into a narrow osseous canal. By opening the lacrimal sac longitudinally, this location can be thoroughly inspected.

The conjunctival incision heals rapidly; however, the indwelling catheter needs to be left in place for at least 2–3 weeks to minimize scarring and closure of the canaliculi and the nasolacrimal duct. The dogs described had their last follow-up examination on a median of 34 days (mean average 104 days) after surgery. At this point in time, the nasolacrimal system was patent in 85% of all cases. It is questionable whether the nasolacrimal system remained permanently patent. It has to be pointed out critically that the need for the placement of a catheter is based on our clinical assumption. Five of seven of our cases that were not patent at the last recheck did not have a catheter placed for various reasons (e.g., patient too small for a catheter, lacrimal sac changes due to long-term dacryocystitis process, owners decline catheter placement). However, three of the cases without a catheter had a patent nasolacrimal duct at the last recheck.

The incision was closed in the one-layer conjunctival suture, lacrimal sac did not require suturing. The lacrimal sac is well identified during surgery (Figure 5C,D).

The lacrimal sac and nasolacrimal duct contain stratified epithelium which rests on a broad basement membrane and stroma just as conjunctiva.<sup>22</sup> In chronic dacryocystitis, the lacrimal sac is friable. Sutures are not only unnecessary as epithelialization takes place quickly but they might actually impede healing. While conjunctiva has shown to epithelialize at a rate of 3.16 mm/day in a rabbit model,<sup>23</sup> suture materials will disturb the conjunctival healing as it will produce varying degrees of inflammation. This may be caused by an up-regulated inflammatory process around the sutures during degradation. Significant inflammation delays wound healing and also reduces the resistance to infection.<sup>24</sup> The sutures we insert to close the conjunctival wound might indeed be superfluous as well. In physician ophthalmology, it is common practice to leave small conjunctival wounds (under 1 cm) to heal without any special attention, and repair with either sutures or tissue glue is only necessary for larger lesions (above 2 cm).<sup>25</sup> However, we do prefer the conjunctival suture in order to close the access to the orbit and thereby prevent possible infections.

To date, this study presents the largest collection of dacryocystotomy cases and their follow-up. Previously, only two studies presented more than four cases of dacryocystitis due to a presumed foreign body. Steinmetz et al. reported removing a foreign body via incision into the lacrimal sac via splitting the canaliculus and leaving it permanently open without placement of the indwelling catheter. In that study, purulent discharge improved immediately, but serous to seromucous discharge prevailed in 8/14 cases and the nasolacrimal duct was patent in 3/6 cases of clinical follow-up.<sup>5</sup> In our study, after using an indwelling catheter, the nasolacrimal duct remained patent in 40 out of 48 cases (86%). They were able to find a foreign body in all of their cases. It is likely that due to long-standing diseases, in our dogs, we have found a foreign body in 41/48 cases (85%). Strom et al. evaluated 16 cases of nasolacrimal apparatus obstruction in dogs with a minimally invasive approach combining computer tomography, lacrimoscopy, and fluoroscopically-guided stenting. Seven of their cases were caused by foreign bodies or granulation tissue from chronic foreign bodies. In this paper, the authors were able to place an indwelling catheter in 14 out of 16 dogs (88%).<sup>26</sup> This is similar to our rate of 83%. However, in our cases, no advanced imaging was used.

In summary, this study presents a new, highly successful transconjunctival approach to the removal of foreign material from the lacrimal sac in order to reestablish the patency of the nasolacrimal system in dogs.

#### AUTHOR CONTRIBUTIONS

**Ingrid Allgoewer:** Conceptualization; data curation; formal analysis; funding acquisition; investigation;

methodology; project administration; resources; supervision; validation; visualization; writing – original draft; writing – review and editing. **Petr Soukup:** Data curation; formal analysis; investigation; methodology; validation; visualization; writing – original draft; writing – review and editing. **Eberhard Ludewig:** Investigation; methodology; visualization; writing – original draft; writing – review and editing.

#### CONFLICT OF INTEREST STATEMENT

The authors declare no conflicts of interest.

#### DATA AVAILABILITY STATEMENT

Data available in article supplementary material.

#### ETHICS STATEMENT

The retrospective study was approved by the responsible authority (Landesamt für Gesundheit und Soziales, Berlin, Germany) under the registration number StN° 033-23.

#### ORCID

Ingrid Allgoewer  <https://orcid.org/0000-0002-2939-4213>

[org/0000-0002-2939-4213](https://orcid.org/0000-0002-2939-4213)

Petr Soukup  <https://orcid.org/0000-0001-6125-8580>

#### REFERENCES

1. Stades FC. Dacryocystomaxillostomy: a new surgical treatment for dacryocystitis (dog). *Tierarztl Prax.* 1978;6:243-250.
2. Laing E, Spiess B, Binnington A. Dacryocystotomy: a treatment for chronic dacryocystitis in the dog. *J Am Anim Hosp Assoc.* 1988;24:223-226.
3. Pope ER, Champagne ES, Fox D. Intraosseous approach to the nasolacrimal duct for removal of a foreign body in a dog. *J Am Vet Med Assoc.* 2001;218(4):541-542. doi:10.2460/javma.2001.218.541
4. Giuliano EA, Pope ER, Champagne ES, Moore CP. Dacryocystomaxillostomy for chronic dacryocystitis in a dog. *Vet Ophthalmol.* 2006;9(2):89-94. doi:10.1111/j.1463-5224.2006.00443.x
5. Steinmetz A, Dohmann GWJ, Blobner CC. Dacryocystitis in dogs caused by foreign bodies—diagnosis and therapy in 14 cases. *Vet Ophthalmol.* 2022;25(2):180-185. doi:10.1111/vop.12968
6. Barsotti G, Mannucci T, Citi S. Ultrasonography-guided removal of plant-based foreign bodies from the lacrimal sac in four dogs. *BMC Vet Res.* 2019;15(1):76. doi:10.1186/s12917-019-1817-9
7. Budras KD, McCarthy PH, Fricke W, Richter R, Horowitz A, Berg R. *Anatomy of the Dog: An Illustrated Text.* 5th ed. Schluetersche; 2007.
8. Schaller O. *Illustrated Veterinary Anatomical Nomenclature.* 1st ed. Enke; 1992.
9. Nöller C, Henninger W, Grönemeyer DHW, Hirschberg RM, Budras KD. Computed tomography-anatomy of the normal feline nasolacrimal drainage system. *Vet Radiol Ultrasound.* 2006;47(1):53-60. doi:10.1111/j.1740-8261.2005.00105.x
10. Michel G. Beitrag zur Anatomie der Tränenorgane von Hund und Katze. *Dtsch Tierarztl Wochenschr.* 1955;62:347-349.

11. Murphy CJ, Samuelson DA, Pollock RVH. The eye. In: Evans HE, Lahunta AD, eds. *Miller's Anatomy of the Dog*. 4th ed. Saunders; 2012:746-785. Saunders.
12. Oechtering TH, Oechtering GU, Nöller C. Strukturelle Besonderheiten der Nase brachycephaler Hunderassen in der Computertomographie. *Tierarztl Prax Ausg K Kleintiere Heimtiere*. 2007;35(3):177-187. doi:10.1055/s-0038-1622615
13. Sahr S, Dietrich A, Oechtering G. Evaluating malformations of the lacrimal drainage system in brachycephalic dog breeds: a comparative computed tomography analysis. *PLoS ONE*. 2021;16(9):e0257020. doi:10.1371/journal.pone.0257020
14. Schlueter C, Budras KD, Ludewig E, et al. Brachycephalic feline noses: CT and anatomical study of the relationship between head conformation and the nasolacrimal drainage system. *J Feline Med Surg*. 2009;11(11):891-900. doi:10.1016/j.jfms.2009.09.010
15. Rached PA, Canola JC, Schlüter C, et al. Computed tomographic-dacryocystography (CT-DCG) of the normal canine nasolacrimal drainage system with three-dimensional reconstruction. *Vet Ophthalmol*. 2011;14(3):174-179. doi:10.1111/j.1463-5224.2010.00861.x
16. GelattKN, CureTH, GuffyMM, JessenC. Dacryocystorhinography in the dog and cat. *J Small Anim Pract*. 1972;13(7):381-397. doi:10.1111/j.1748-5827.1972.tb06864.x
17. Yakely W, Alexander J. Dacryocystorhinography in the dog. *J Am Vet Med Assoc*. 1971;159(11):1417-1421.
18. Nykamp SG, Scrivani PV, Pease AP. Computed tomography dacryocystography evaluation of the nasolacrimal apparatus. *Vet Radiol Ultrasound*. 2004;45(1):23-28. doi:10.1111/j.1740-8261.2004.04004.x
19. Schultz RM, Zwingenberger A. Radiographic, computed tomographic, and ultrasonographic findings with migrating intrathoracic grass awns in dogs and cats. *Vet Radiol Ultrasound*. 2008;49(3):249-255. doi:10.1111/j.1740-8261.2008.00360.x
20. Vansteenkiste DP, Lee KCL, Lamb CR. Computed tomographic findings in 44 dogs and 10 cats with grass seed foreign bodies. *J Small Anim Pract*. 2014;55(11):579-584. doi:10.1111/jsap.12278
21. Lafuma F, Tréhiou CB, Bernardin F, Blond L. Computed tomography may be helpful in discriminating grass awn foreign body rhinitis from non-foreign body rhinitis in dogs. *Vet Radiol Ultrasound*. 2021;62(5):533-540. doi:10.1111/vru.12981
22. Paulsen F, Thale A, Kohla G, et al. Functional anatomy of human lacrimal duct epithelium. *Anat Embryol*. 1998;198(1):1-12. doi:10.1007/s004290050160
23. Zhu X, Beuerman RW, Cheng ZY, Ang LPK, Tan DTH. Kinetic analysis of conjunctival epithelial wound healing in the rabbit model. In: *ARVO Annual Meeting Abstracts*. Vol. 46. 2005:4247.
24. Anand K, Goyal G, Goel Y, Bansal Y, Rastogi A, Jaisingh K. Ocular surface response to fibrin sealant versus vicryl suture for conjunctival closure after strabismus surgery: an objective assessment. *Saudi J Ophthalmol*. 2021;34(4):243-246. doi:10.4103/1319-4534.322602
25. Comez AT, Ozbas M. Evaluation and management of ocular traumas. In: *Vision Correction and Eye Surgery* IntechOpen; 2022. doi:10.5772/intechopen.101776
26. Strom AR, Culp WTN, Leonard BC, et al. A multidisciplinary, minimally invasive approach combining lacrimoscopy and fluoroscopically guided stenting for management of nasolacrimal apparatus obstruction in dogs. *J Am Vet Med Assoc*. 2018;252(12):1527-1537. doi:10.2460/javma.252.12.1527

## SUPPORTING INFORMATION

Additional supporting information can be found online in the Supporting Information section at the end of this article.

**How to cite this article:** Allgoewer I, Soukup P, Ludewig E. A transconjunctival surgical technique for dacryocystotomy in dogs with foreign body-induced dacryocystitis. *Vet Ophthalmol*. 2024;00:1-9. doi:10.1111/vop.13214